



# Sagittal Balance

Radiographic Assessment  
And  
Surgical Goals



FLORIDA ORTHOPAEDIC INSTITUTE

Steven J. Tresser, MD



---

---

---

---

---


---

---


---

## Disclosures

- Nuvasive – consultant, royalties, speaking
- K2M – consultant, royalties
- Centinel Spine – consultant, speaking
- CTL Medical – advisory board



FLORIDA ORTHOPAEDIC INSTITUTE



---

---

---

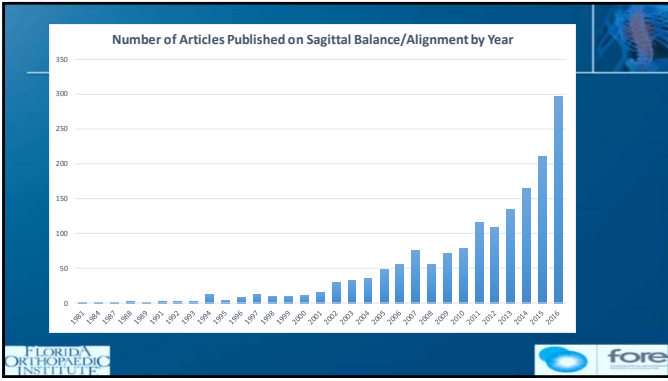
---

---

---

---

---



---

---

---

---

---

---

---

---

## Sagittal Balance

- How do we determine/measure it
- Why should we care about it?
- Defining surgical goals
- History of the problem and thought development
- How to plan surgeries using this information
- Future directions

FLORIDA ORTHOPAEDIC INSTITUTE

---

---

---

---

---

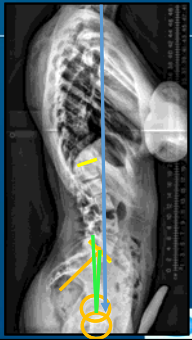
---

---

---

## The Spinopelvic Parameters

1. Lumbar Lordosis (LL)
2. Pelvic Incidence (PI)
3. Pelvic Tilt (PT)
4. Sagittal Vertical Axis (SVA)



FLORIDA ORTHOPAEDIC INSTITUTE

---

---

---

---

---


---

---

---

## Lumbar Lordosis

- L1-S1 angle
- Normal lumbar lordosis is within the range of  $63^\circ \pm 15^\circ$
- Relates to pelvic incidence
  - Normal PI -LL =  $\pm 9^\circ$
- **At least 2/3 of LL is at L4-S1**



FLORIDA ORTHOPAEDIC INSTITUTE

---

---

---

---

---

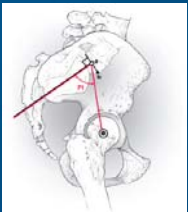
---

---

---

### Pelvic Incidence

- Angle between the perpendicular to mid-sacral endplate and femoral heads
- PI determines relationship to rest of spine
- Everyone's pelvis is different
- Stays constant throughout adult life
- Not affected by patient position
- Rocking your pelvis backwards doesn't change it



FLORIDA ORTHOPAEDIC INSTITUTE fore

---

---

---

---

---

---

---

---

### So What is The PI/LL Connection?



FLORIDA ORTHOPAEDIC INSTITUTE fore

---

---

---

---

---



---

---

---

### Normal Sagittal Alignment

Pelvic Incidence and Lordosis

 <p><b>Large PI</b> Horizontal sacrum Marked, long lordosis</p>	 <p><b>Small PI</b> Vertical sacrum Flat lordosis</p>
--	--

FLORIDA ORTHOPAEDIC INSTITUTE fore

---

---

---

---

---


---



---

---

### Pelvic Tilt

- Angle between the vertical and line drawn from mid-sacral endplate to femoral heads
- Normal pelvic tilt is **less than 20 degrees**
- Compensatory mechanism to reduce positive balance



---

---

---

---

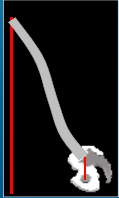
---

---


---

---


### Compensation and Pelvic Tilt



Large SVA, No PT





Moderate SVA / PT



No SVA, Large PT

**Large Pelvic Tilt => Hip Hyper-extension  
Compromises Walking**

---

---

---

---

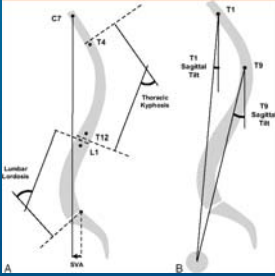
---



---

---

---

### SVA/T<sub>r</sub>SP



---

---

---

---

---



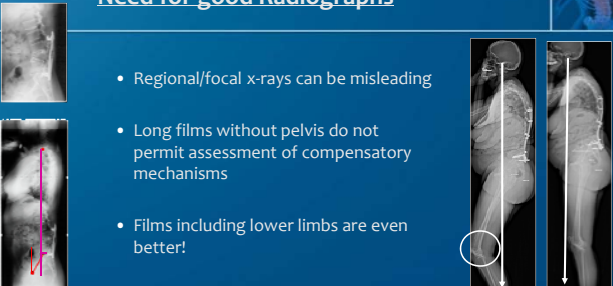
---

---

---

### Need for good Radiographs

- Regional/focal x-rays can be misleading
- Long films without pelvis do not permit assessment of compensatory mechanisms
- Films including lower limbs are even better!



---

---

---

---

---




---

---

---

### At a minimum

- Lumbar radiographs that include the femoral heads
  - Able to derive a PI, LL, and PT
  - Allows awareness of 'at risk' patients



---

---

---

---

---

---



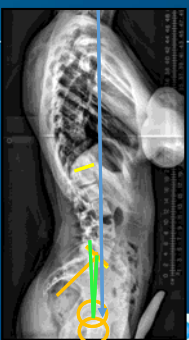
---

---

### The Spinopelvic Parameters

So....

How can we use all this to help our patients??



---

---

---

---

---

---

---

---



### Goals for Sagittal Balance

Alignment Objectives<sup>1</sup>

1.  $PI - LL < 10^\circ$
2.  $PT < 20^\circ$
3.  $SVA < 5cm$

<sup>1</sup>Schwab F, Ungar B, Blondel B, et al. Scoliosis Research Society - Schwab adult spinal deformity classification. A validation study. *Spine* 2012;37(12):1077-82.

FLORIDA ORTHOPAEDIC INSTITUTE | fore

---

---

---

---

---

---

---

---

---

---

### How Can We Use This to Plan?

- Pre-operative planning
  - Identify if sagittal balance needs to be addressed
  - Identify/quantify the extent of problem
  - Plan/simulate cages and osteotomies
- Intra-operative assessment
- Inter-stage assessment
- Post-operative confirmation

FLORIDA ORTHOPAEDIC INSTITUTE | Castellvi Spine 2016 | fore

---

---

---

---

---

---

---

---

---

---

### Steps for Pre-operative Planning

- Measure pelvic parameters
- Remove compensation (PT)
- Measure global alignment (SVA, T1SP, TPA)
- Determine amount of correction needed/desired
- Consider other factors
- Plan levels needed to correct balance
- Simulate cages and osteotomies

FLORIDA ORTHOPAEDIC INSTITUTE | Castellvi Spine 2016 | fore

---

---

---

---

---

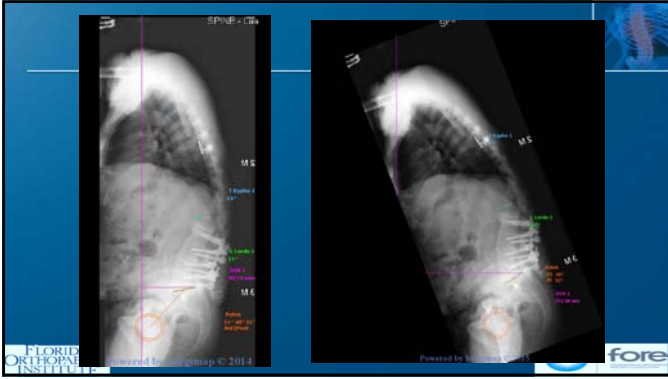
---

---

---

---

---



---

---

---

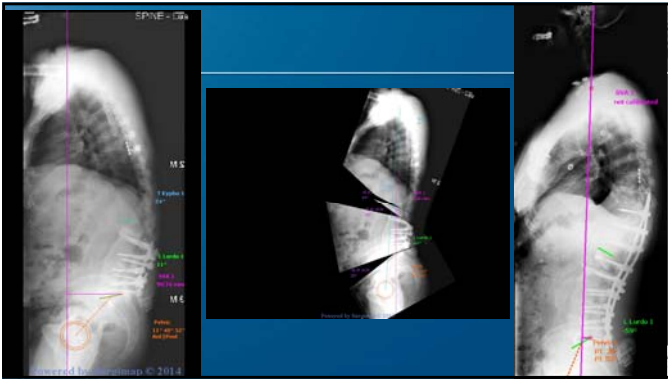
---

---

---

---

---



---

---

---

---

---

---

---

---