The Glenoid in Anatomic Shoulder Arthroplasty: Top 10 Glenoid Technique Tips

T. Bradley Edwards, M.D.
Christopher M. Kilian, M.D.
Fondren Orthopedic Group
Texas Orthopedic Hospital
Houston, Texas

Disclosure for T. Bradley Edwards, MD

a. Consulting/Royalty payments directly related to products discussed (Tornier)
b. Consulting/Royalty payments for other products from the same company as the products discussed (Tornier)
c. Research or other financial support from the same company as the products discussed (Tornier)

Introduction

1) Preoperative Planning

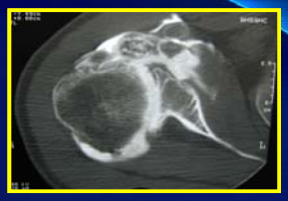

- Imaging
  - CT
  - MRI

1) Preoperative Planning

- Walch Classification:

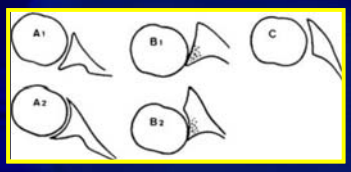

2) Implant Choice

- Reverse
  - Severe glenoid bone loss
  - Older patient

3) Glenoid Exposure

- Inferior capsular release

3) Glenoid Exposure

3) Glenoid Exposure

- Critical in glenoid implantation
  - Inferior capsular release
  - Neuromuscular paralysis
  - Gradual tissue elongation

4) Glenoid Preparation

- Reaming
  - Correct deformity
  - Create surface to match back of implant
  - May require removal of subchondral bone

4) Glenoid Preparation

- Walch et al, *J Bone Joint* Surg, 2012
  - 3 patterns of loosening identified
    - Subsidence
    - Superior tilt
    - Posterior tilt
  - Subsidence and posterior tilt associated with reaming subchondral bone

4) Glenoid Preparation

- Radius of curvature gauges
  - Measure radius of curvature of native glenoid

4) Glenoid Preparation

- Reamers
  - Matched to measured radius of curvature
  - Minimal bone removal
  - Subchondral bone preserved
  - Components match native radius of curvature

5) Correction of Deformity



- Biconcave glenoid
  - Difficult to identify intraoperatively

5) Correction of Deformity

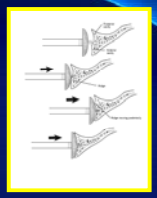

- Biconcave glenoid
  - Will require removal of some subchondral bone
  - Center hole will “migrate” anteriorly during reaming
  - Reverse?

6) Prosthetic Mismatch

- Prosthetic mismatch is the difference of the radius of curvature between the glenoid component and the humeral head component (R – r)

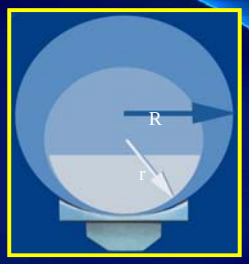

6) Prosthetic Mismatch

- Conforming
  - mismatch = 0
  - stable
  - minimal wear
  - increase potential for loosening secondary to obligate translation





6) Prosthetic Mismatch

- Nonconforming
  - mismatch > 0
  - allows translation
  - ↓ stress
  - ↑ wear
  - ↓ stability







6) Prosthetic Mismatch

- Ideal prosthetic mismatch may be in excess of 5.5 mm

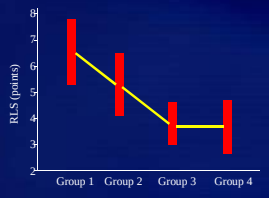

7) Glenoid Component

↔

- Keel vs. peg
  - Peg better for radiolucent lines
    - 2 years and 5 years

8) Intraoperative Trialing

- Critical for biconcave glenoid
- Arm held in 30 degrees external rotation and posteriorly directed force applied

9) Soft Tissue Balancing

- Soft tissues corrected in most cases by use of anatomic implant
- Biconcave glenoid is exception
  - Posterior capsular distension

9) Soft Tissue Balancing

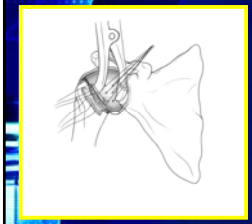

- Posterior capsulorrhaphy if necessary

10) Rehabilitation

- Neutral rotation to protect posterior capsulorrhaphy

10) Rehabilitation



- Aquatic therapy
- Protect subscapularis/posterior capsulorrhaphy

Thank You