


Subtle Cavovarus Foot

Arthur Manoli, II, MD
Tampa, 2017

Disclosure

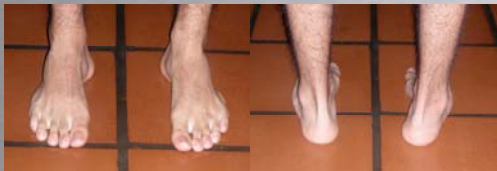Royalties, Arch Rival® shoe insert for cavus foot

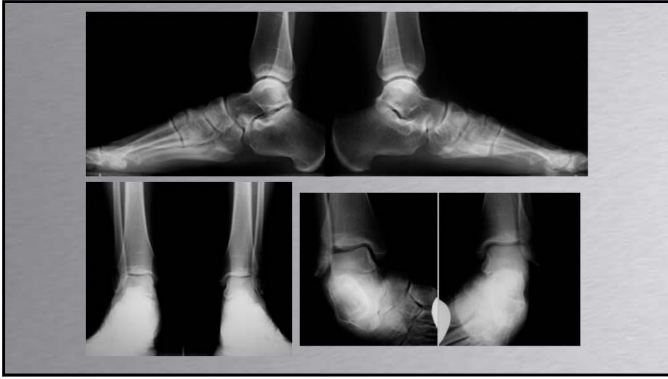


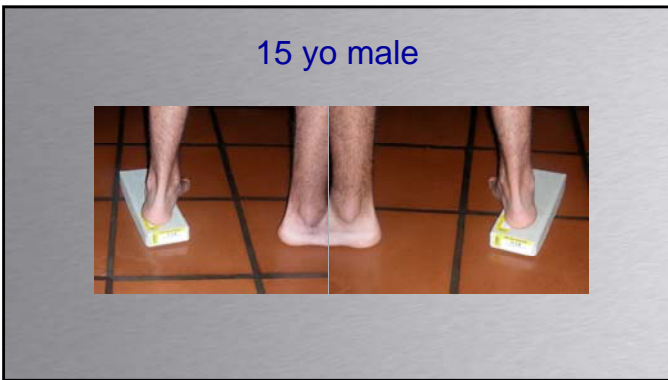


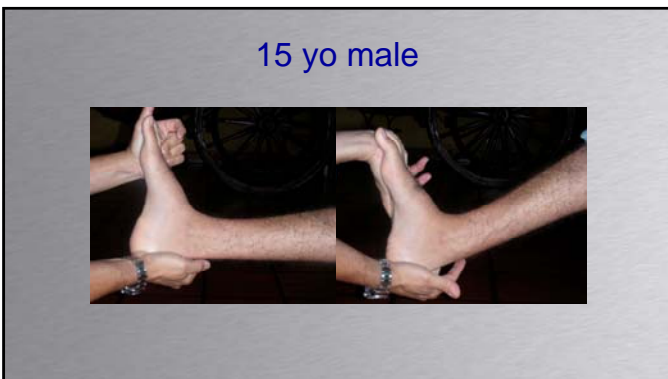15 yo male, recurrent sprains R ankle

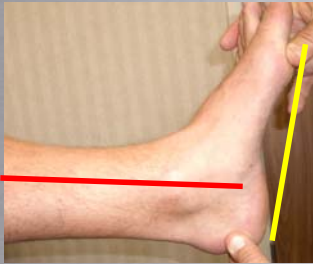






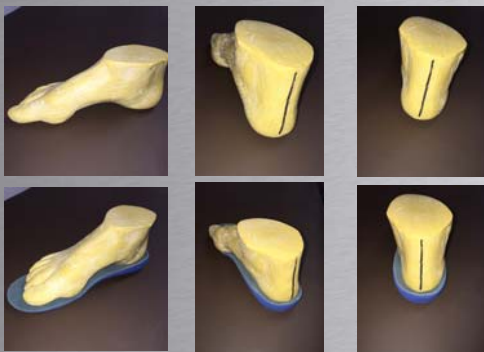


Gastrocnemius Tightness



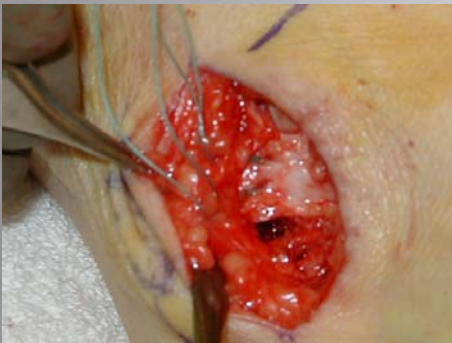"Orthotic"





Arch Rival®

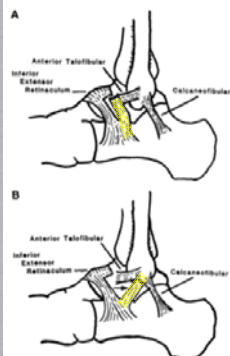


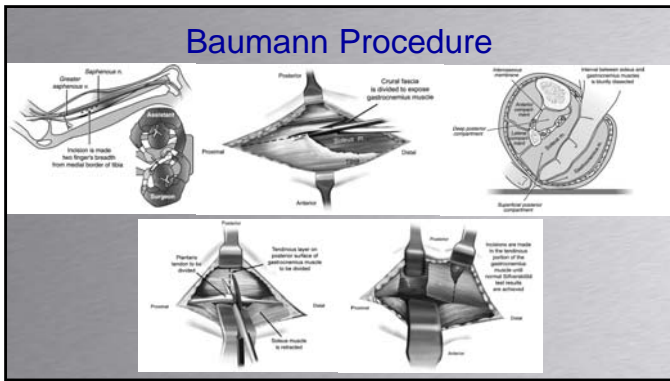


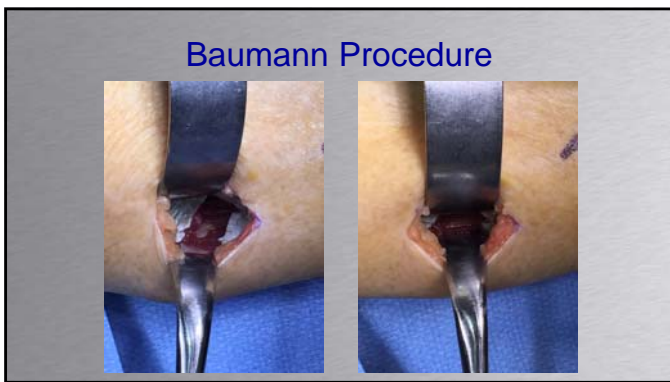
© 2012 Lippincott Williams & Wilkins
All rights reserved. This publication is protected by copyright.
Unauthorized reproduction or distribution is prohibited without written permission from the copyright holder.

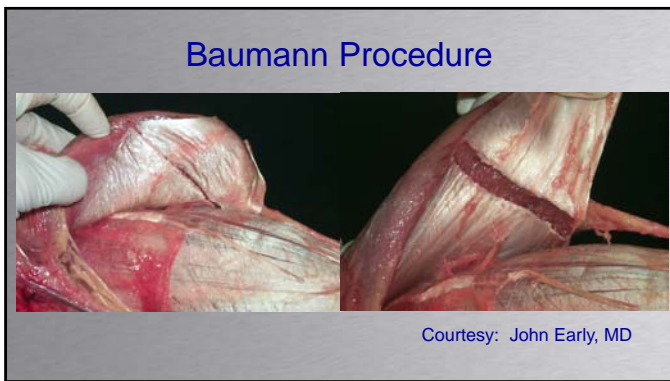
Technique Tip Modification of the Gould Modification of the Broström Ankle Repair

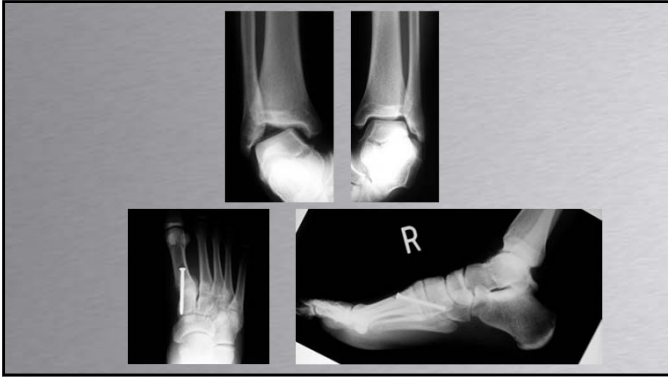Markus C. Hepler, M.D.
Dunwoody, Tennessee

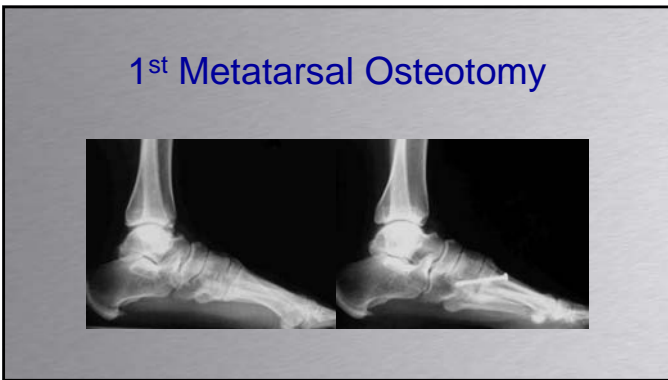


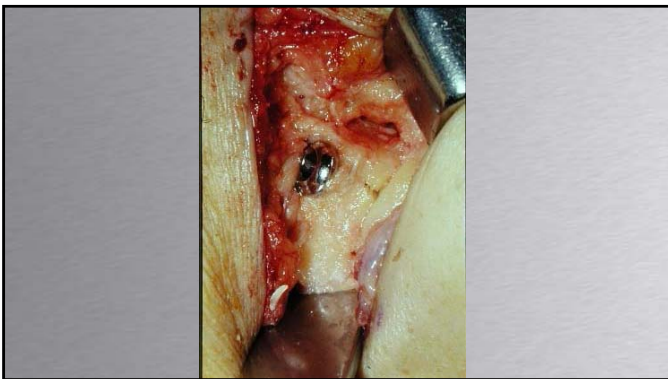


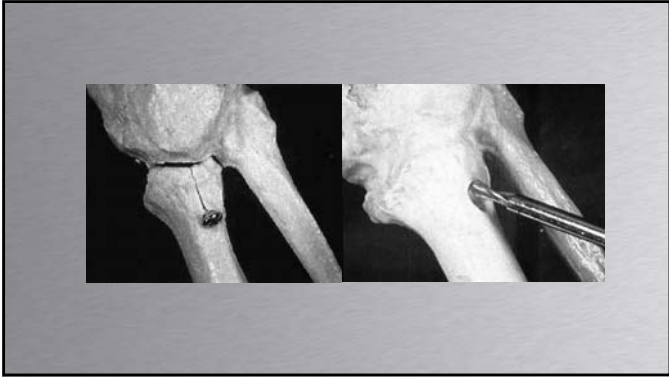


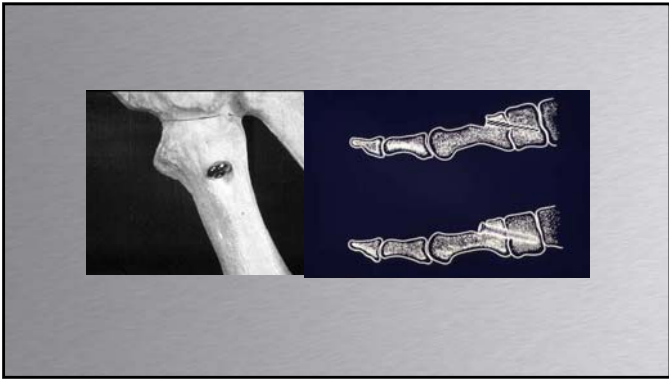








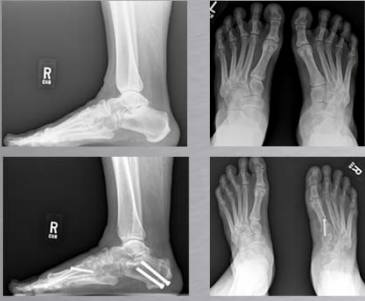





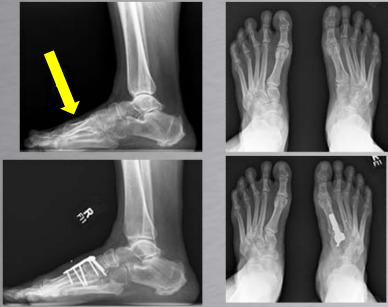
Peroneus Longus to Peroneus Brevis ?

54 yo female

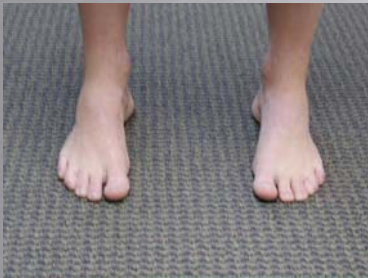

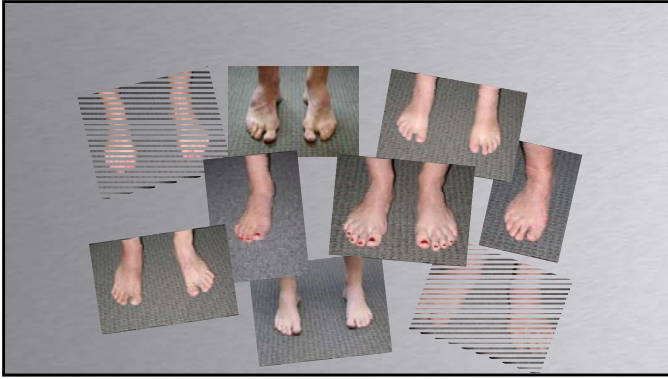
Peroneus Longus to Peroneus Brevis ?

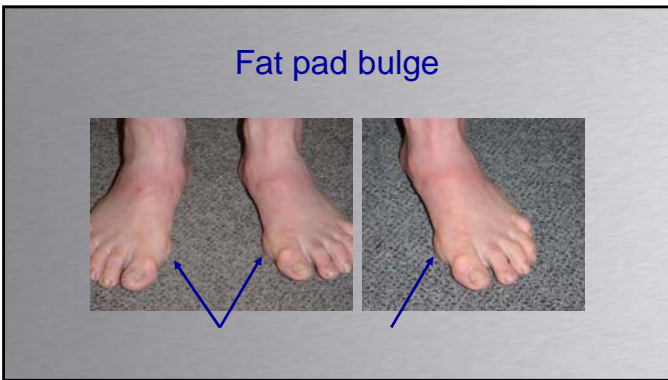
54 yo female

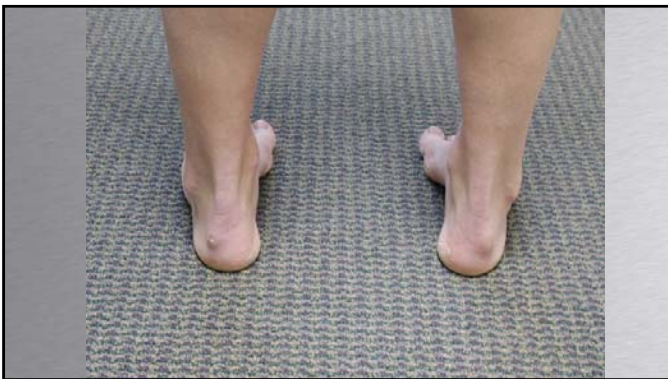

Peek-A-Boo Heel Sign

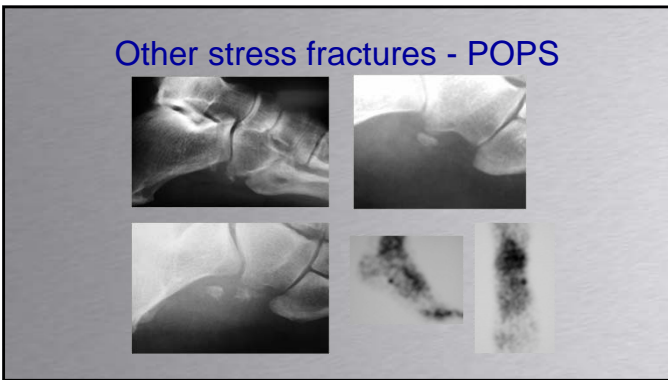


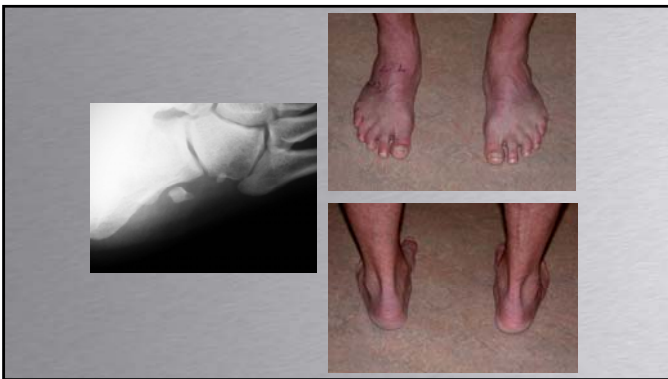




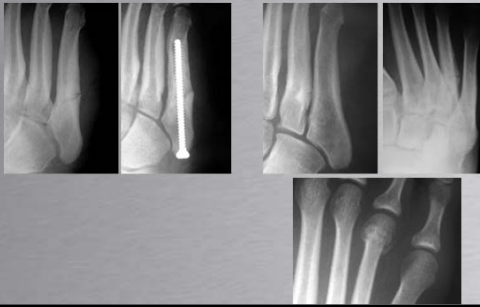




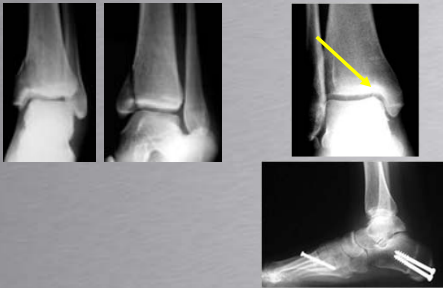

Other stress fractures

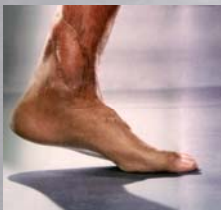

Other stress fractures

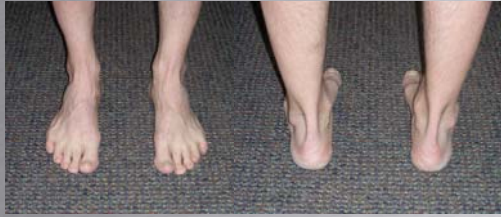



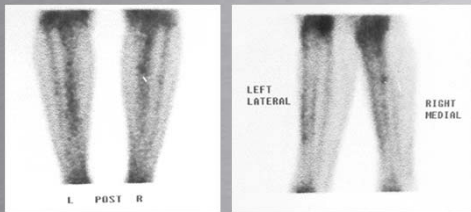
The first three operations merely reset the bone—"changed the flat," as Hill liked to say. The fourth operation had finally got it right, a full realignment that involved breaking and restructuring his ankle and heel.



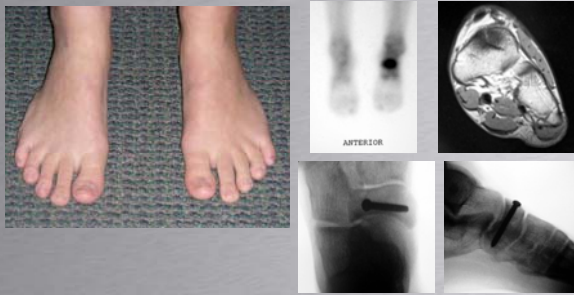Stress Fractures

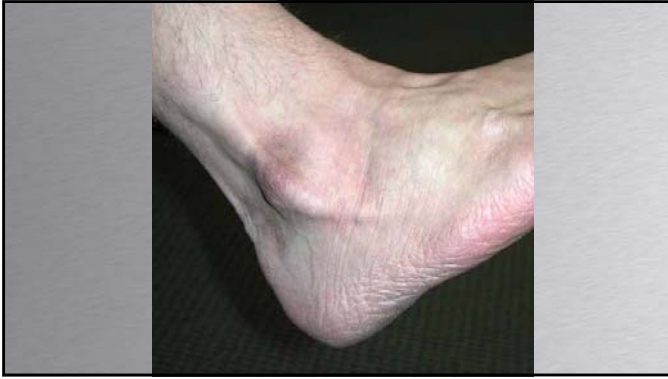

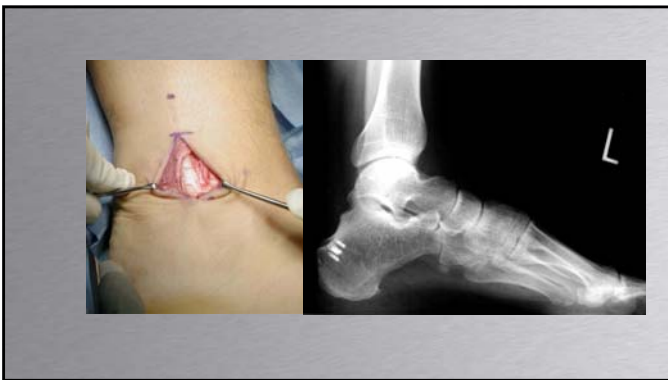
Stress Fractures

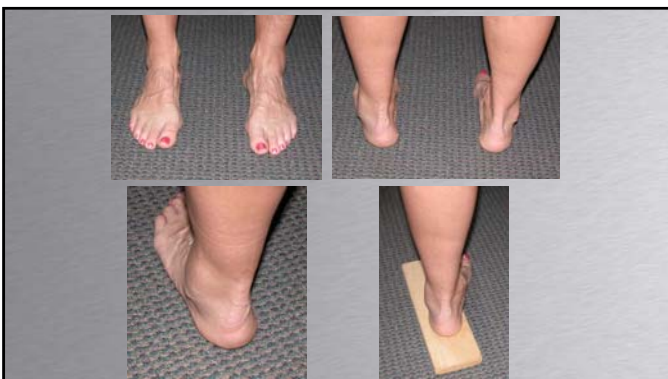

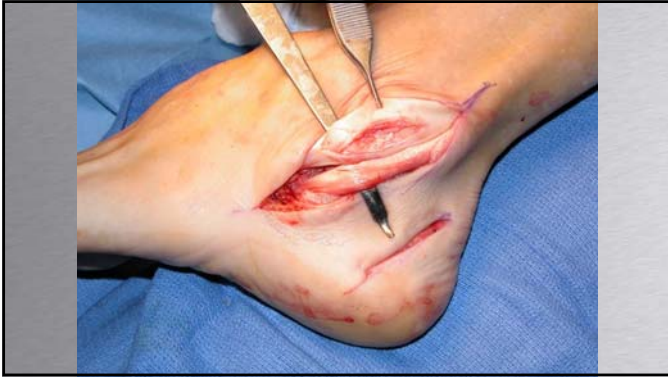Stress Fractures

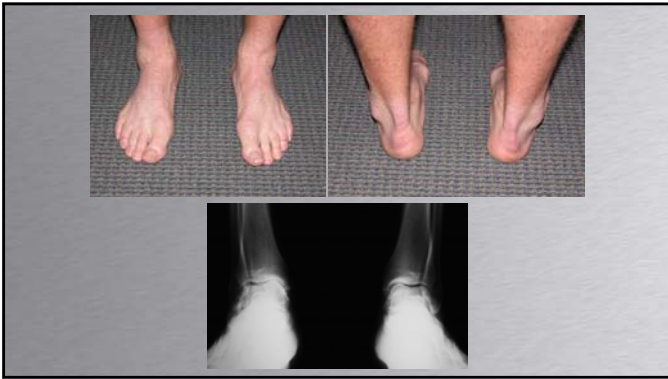


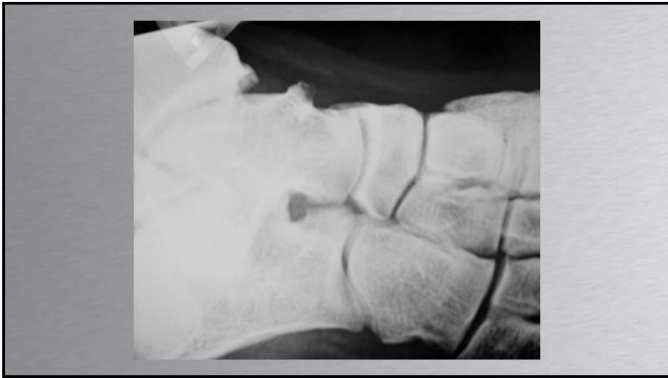
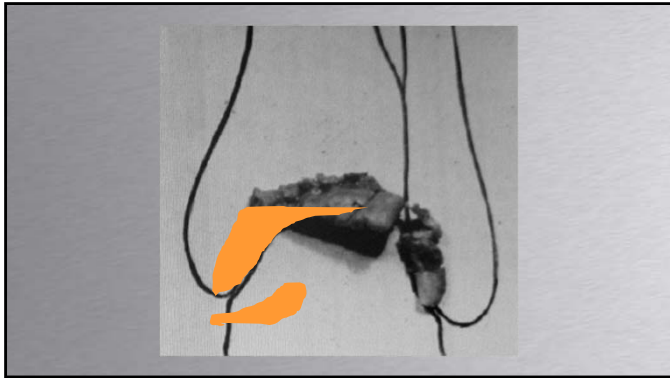




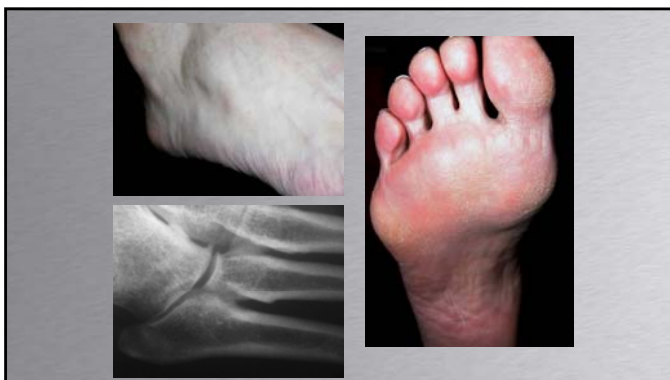









Conclusions

Identify
Coleman Block
1st metatarsal osteotomy
Heel osteotomy
PL to PB ????

Fix associated condition