Bisphosphonate Related Femur Fractures: Acute Management And Nonunion Treatment

Michael T. Archdeacon, M.D., M.S.E.

Peter J. Stern Professor & Chairman
Department of Orthopaedic Surgery
University of Cincinnati Medical Center

November 21, 2016

UC Health Orthopaedics & Sports Medicine

Tips & Tricks: Proximal Femur Fractures

Michael T. Archdeacon, M.D., M.S.E.

- Paid Consultant for Stryker Trauma
- Royalties: Stryker; SLACK Inc.
- Research Support: OTA
- Deputy Editor: JAAOS
- Editorial Review Board: JBJS; CORR; JOT
- Organizational Boards: OTA, Ohio Orthopaedic Society

UC Health Orthopaedics & Sports Medicine

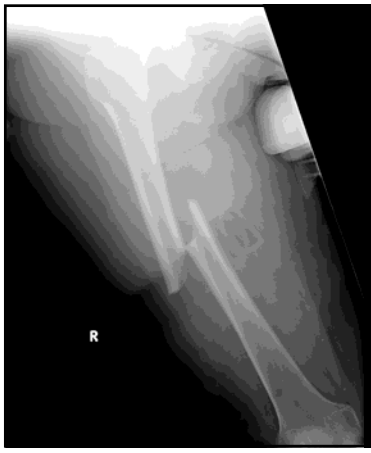

The Problem

UC Health Orthopaedics & Sports Medicine

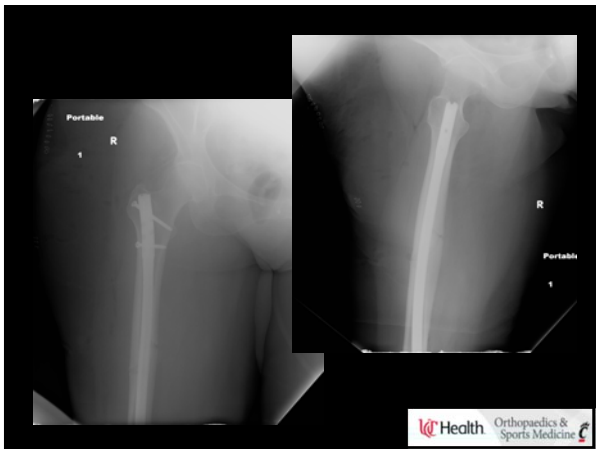

Bisphophonates

Epidemiologic Problem
- Osteoporosis & Fractures
- Resultant Increased Death, Morbidity, Cost, Effects On Independence & Quality Of Life

Epidemiologic Solution
- Bisphosphonates
  - Alendronate, Residronate, Ibandronate, Zoledronate

Health Orthopaedics & Sports Medicine

Bisphosphonates

Alendronate…How it works
- Target…Osteoclasts
  - Binds To Inorganic Component Of Bone
  - Bound Alendronate Released During Resorption
  - Endocytosed By Osteoclasts
  - Inhibits Mevalonate Pathway For Cholesterol Synthesis
  - Induced Osteoclast Apoptosis
- Result…Increased BMD

Health Orthopaedics & Sports Medicine

Bisphosphonates

Increased BMD…At What Cost?

Decreased Bone Resorption, Remodeling, Microdamage Repair, Mechanical Integrity, etc.

- Allen et al; *Bone* 2010
- Mashiba et al; *Bone* 2001
- Odvina et al; *J Clin Endocrinol Metab* 2005
- Mashiba et al; *J Bone Miner Metab* 2005
- Burr et al; *J Bone Miner Res* 1997
- Cao et al; *J Bone Miner Res* 2002

- ***Femoral Stress Fracture?***

UC Health Orthopaedics & Sports Medicine

Low Energy Femur Fractures Associated With Alendronate Use

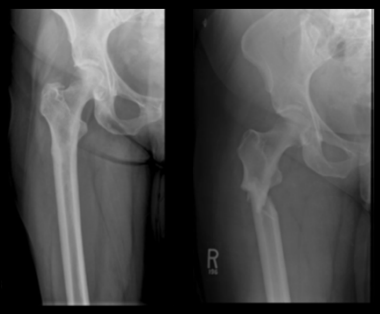

UC Health Orthopaedics & Sports Medicine

A Growing Problem

- Pubmed Search
  - "Bisphosphonate Femur" = 1114 Citations
  - "Bisphosphonate AND Femur Fracture" = 874 Citations

UC Health Orthopaedics & Sports Medicine

Bisphosphonates And The Femur

Goh et al; *JBJS Br* 2007

- 13 Low-Energy Subtrochanteric Fractures
  - 9 On Alendronate (Mean 4.2yrs)
  - 5 With Prodromal Pain
  - 3 With Contralateral Stress Reaction

UC Health Orthopaedics & Sports Medicine

Bisphosphonates And The Femur

Nevaiser et al; *J Orthop Trauma* 2008

- 70 Low-energy Femur Fractures
- 36% Treated With Alendronate
  - 76% Demonstrated Characteristic Fracture Pattern
  - Duration Of Alendronate Use: 6.9 Years
- Only 1 Patient *Not* On Alendronate Showed This Same Pattern (Dx Multiple Myeloma)

UC Health Orthopaedics & Sports Medicine

Bisphosphonates And The Femur

Kweck et al; *Injury* 2008

- 17 Low-energy Fractures
  - Alendronate 4.8 Yrs
  - 53% With Contralateral Stress Reaction
  - 76% With Prodromal Pain
  - Similar Fracture Patterns

UC Health Orthopaedics & Sports Medicine

Bisphosphonates And The Femur

Isaacs et al. *CORR* 2010

- 100 Low-energy Fractures
- 21 Pre-Bisphosphonate (1997)
  - None "Insufficiency-type"
- 79 Post-Bisphosphonate
  - 41 On Alendronate
    - ✓71% Prodromal Pain
    - ✓44% Bilateral
- Alendronate Use + Fracture
  - Mean 7.1 Years
  - Versus 3.2 Years Without Fracture

UC Health Orthopaedics & Sports Medicine

Bisphosphonates And The Femur

72 Year-old Female With Lateral Thigh Pain On Weight Bearing. On Alendronate For Last 5 Years.

What Should I Do?

UC Health Orthopaedics & Sports Medicine

Day Of Presentation

UC Health Orthopaedics & Sports Medicine

Day Of Presentation

Bisphosphonates And The Femur

What Is The Likelihood Of A Non-Operatively Treated Bisphosphonate-Associated Femoral Stress Fracture Progressing To Completion And In What Time Period?

Bisphosphonates And The Femur

Banffy et al; *CORR* 2011

- 34 Patients With 40 Fractures
  - Mean Bisphosphonate Use 6.4 Years
  - 70% (28/40) Completed To Displaced Femur Fractures
  - Time To Fracture Completion = 10 Months (3-18)

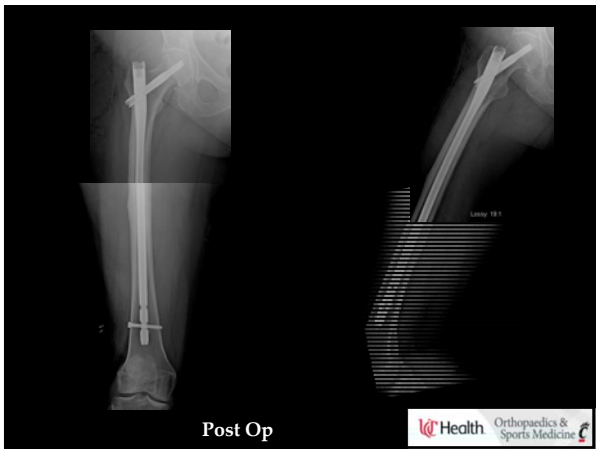
Post Op
UC Health
Orthopaedics & Sports Medicine

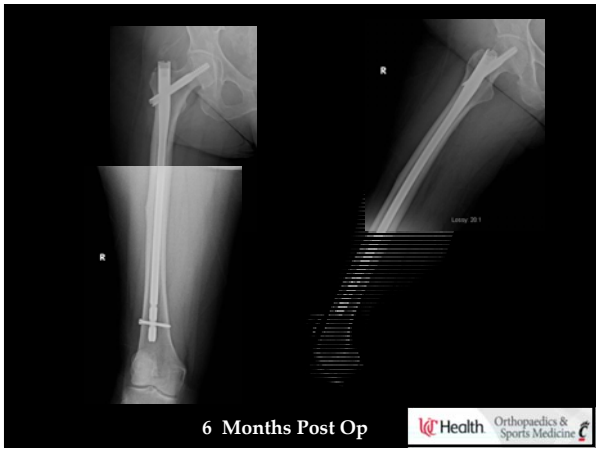
6 Months Post Op
UC Health
Orthopaedics & Sports Medicine

6 Months Post Op
UC Health
Orthopaedics & Sports Medicine

Bisphosphonates And The Femur

If I Treat A Bisphosphonate Associated Atypical Femur Fracture, What Is The Likelihood Of The Fracture To Heal?

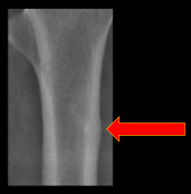

UC Health Orthopaedics & Sports Medicine

J Trauma. 2011 Jul;71(1):186-90. doi: 10.1097/TA.0b013e31821957e3.

The outcome of surgically treated femur fractures associated with long-term bisphosphonate use.

Weil YA[1], Rivkin G, Safran O, Liebergall M, Foldes AJ.

Aim Of This Study Was To Describe The Outcome Of Surgically Treated Femur Fractures (Fx's) Associated With Prolonged Bisphosphonate (BP) Use

- Atypical Femur Fractures

- 15 Pts With 17 Fx's
  - Mean BP Use 7.8 Years (4-13 Years)
  - All Treated With Intramedullary (IM) Rods
    - ✓ 54% Healed
  - 46% Additional Surgery – But All Eventually Healed
- Much Higher Failure Rate With IM Rod Requiring Revision Surgery

UC Health Orthopaedics & Sports Medicine

Clin Orthop Relat Res. 2012 Aug;470(8):2295-301. doi: 10.1007/s11999-012-2412-6. Epub 2012 Jun 6.

Bisphosphonate-associated femur fractures have high complication rates with operative fixation.

Prasarn ML[1], Ahn J, Helfet DL, Lane JM, Lorich DG.

Do Complication Rates Differ In Patients With Operatively Treated Femoral Shaft Fractures Receiving BP And In Patients Not Receiving BP

- 43 Atypical Femur Fx's in BP Pt's Compared With 20 Similar Fx's In Pt's Not Taking BP
  - BP Cohort Had A Higher Rate Of Intraoperative Fractures (21% Versus 0%)
  - BP Cohort Had Higher Rate Of Plate Failures (30% Versus 0%)
- More Sx Complications In The BP Group

UC Health Orthopaedics & Sports Medicine

Clin Orthop Relat Res. 2014 Sep;472(9):2728-34. doi: 10.1007/s11999-013-2963-1.

Healing delayed but generally reliable after bisphosphonate-associated complete femur fractures treated with IM nails.

Egol KA[1], Park JH, Rosenberg ZS, Peck V, Tejwani NC.

Purposes Of This Study
- Evaluate The Percentage Of Patients Who Achieved Radiographic Union Of Atypical Femur Fractures After Sx

- 41 Atypical Femur Fx Pt's With ≥ 5 Years Of BP Therapy
  - Mean BP Therapy 8.8 years (5-20 years)
  - 66% Patients Became Pain Free After Sx
  - 98% Healed By 12 Months
- Reliable Fx Healing, But Delayed Time Frame To Healing

UC Health Orthopaedics & Sports Medicine

Orthopedics. 2012 Jun;35(6):e991-5. doi: 10.3928/01477447-20120525-51.

Treatment of femoral fracture nonunion after long-term bisphosphonate use.

Grady MK[1], Watson JT, Cannada LK.

Case Report Article
- Describes 2 Patients On Long-Term BP Therapy Treated For Atypical Femur Fractures That Failed To Heal With Intramedullary Nailing

- 4.5 Years Of BP Therapy Before Fx
  - Factors Observed
    - ✓ Subtrochanteric Location
    - ✓ Minimal Trauma
    - ✓ Transverse Fracture
    - ✓ Cortical Beaking
- Treated With Nail Removal And Definitive Plating To Achieve Compression Across The Fracture Site

UC Health Orthopaedics & Sports Medicine

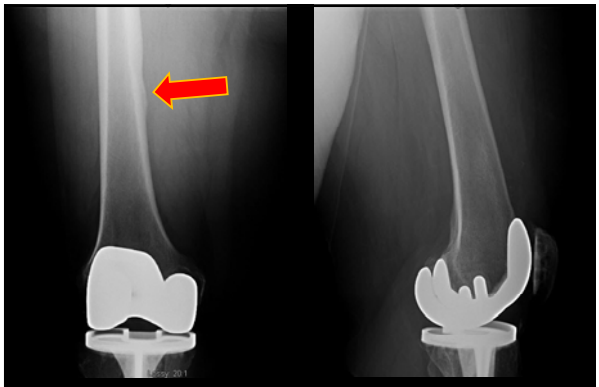

3 Weeks Prior To Injury

UC Health Orthopaedics & Sports Medicine

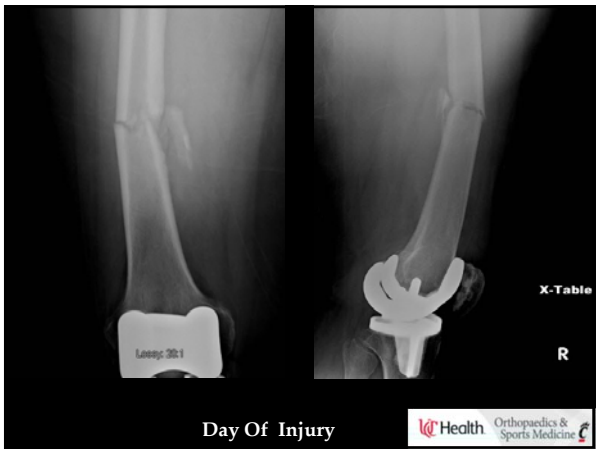

Day Of Injury

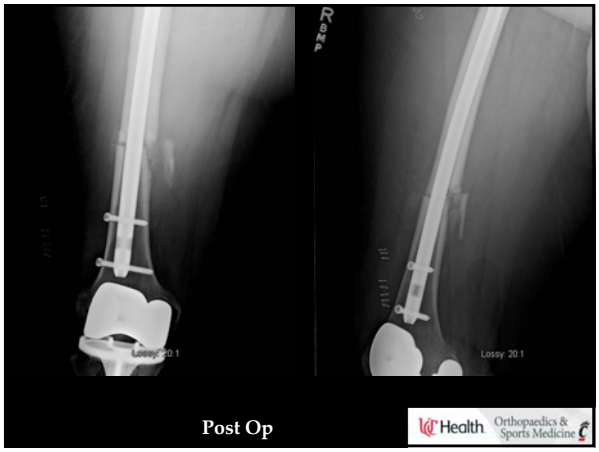

Post Op

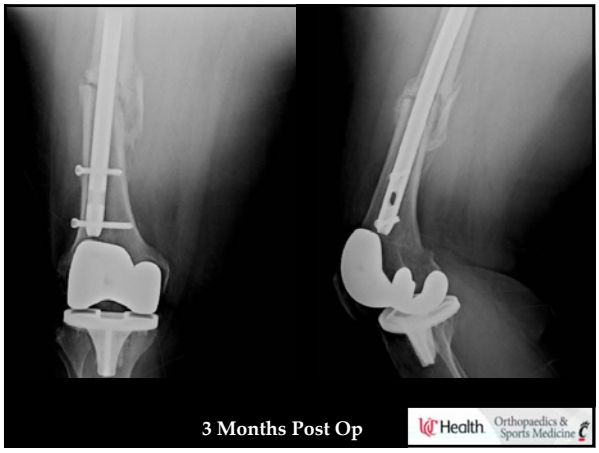

3 Months Post Op

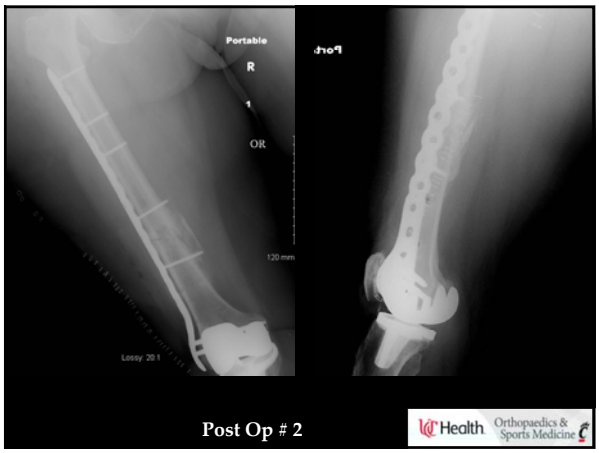

Post Op # 2

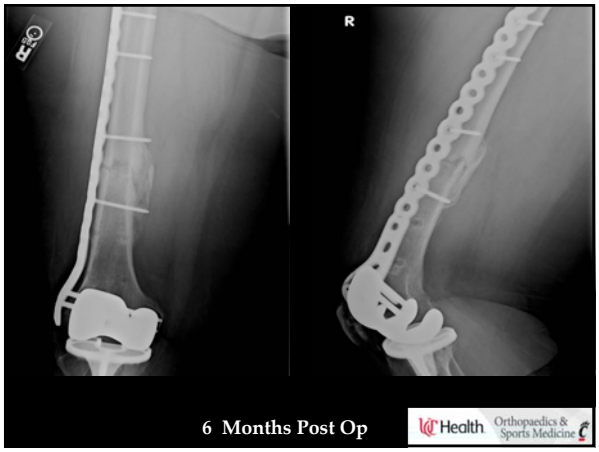

6 Months Post Op

Summary

Atypical Femur Fractures Associated With Long Term BP Use

- Mean Duration Of BP Treatment ≥ 5 Years
- Majority Of Patients Are Treated With IM Rod
- Failure To Heal With First Surgery 2-46%
- Compression Across Nonunion With Plate Heals Nonunion In Some Case Reports
- Revision Surgical Treatment With IM Rod May Also Be Reasonable
- Many Factors Remain Unknown

Thank You
UC Health
Orthopaedics & Sports Medicine