Lateral Wall Failure Proximal Femoral Fractures

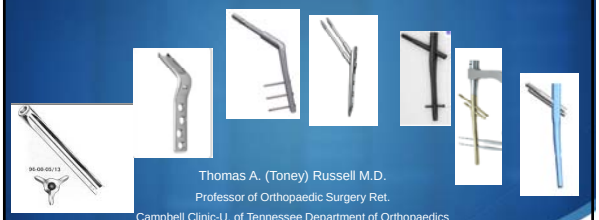

Thomas A. (Toney) Russell M.D.
Professor of Orthopaedic Surgery Ret.
Campbell Clinic-U. of Tennessee Department of Orthopaedics
University of Tennessee Center for the Health Sciences
Elvis Presley Trauma Center

COI Disclosure

ZimmerBiomet: Consultant, Inventor, Trauma, ETEX, Knee Creations

Smith & Nephew, Nails and Plates, Memphis, TN

Intellectual Property Contracts

Textbook Contracts: Hip Fractures: Techniques in Orthopaedic Surgery 2nd Ed, Lippincott Williams and Wilkins, Surgical Treatment of Orthopaedic Trauma 2nd Ed. Thieme Publishers, New York, Rockwood and Green's Fractures in Adults 8th Ed, Lippincott Williams and Wilkins.

Modern Failure Model If Fixation/Reduction Permits Excessive Rotation

Rotation Combined With Sliding=Bone Erosion
↓
Instability
↓
Collapse
↓
Distortion of Hip Mechanics
↓
Pain, Disability and Death

Pantrochanteric Hip Fracture: Lateral Wall Failure
Gotfried. J Ortho Trauma 2012

The Pantrochanteric Hip Fracture: An Iatrogenic Entity

Conversion of A1 or A2 to A3 Fracture

What Is Lateral Wall Failure? "You Never See What Your Not Looking For"

- Not New
- Rediscovery of A Complication
- Surgically Induced
- Specific Implant Related Morbidity
- Fracture Can Be Neutralized By Implant Selection

COMPRESSION HIP SCREWS – THE GOLD STANDARD Vs. IM Nails

What Is Wrong With This Picture?

1980's Company Technique Manual

CHS: Collapse to Stability
Medialization of the Shaft

Lateral Disruptive Trochanteric Insertion
Varus of Hip

Fracture and Dislocation Classification Compendium
J. Orthop Trauma 21(10)Supplement
2007 OTA/AO Classification

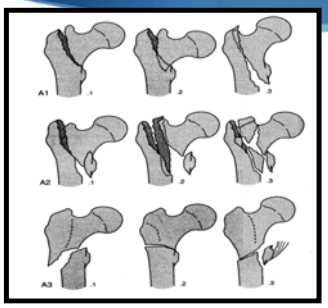

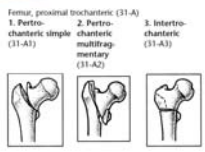

No Lateral Evaluation

3 Part Intertrochanteric Fx
My Initiation 1998

Note Initial Compression and Sliding At 6 Wks
Something Happening At Greater Trochanteric Region

TAR CASE 1998

2 Years Post Injury
Unusual Non-Union: No Cut Out
Implant Collapse and Shaft Screw Failure

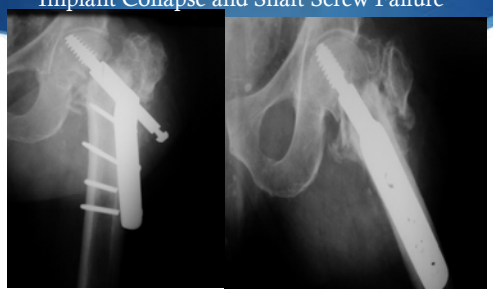

Non-Union of Femoral Neck <u>And</u>
Greater Trochanter From an IT Fracture?

Use of an Intramedullary Hip-Screw Compared with a Compression Hip-Screw with a Plate for Intertrochanteric Femoral Fractures

A Prospective, Randomized Study of One Hundred Patients*

Hardy Et al
JBJS 1998

Level I
Evidence
CHS Vs.
IMHS

Hardy et al Results Unstable Fractures 1998

Treatment	Nail	CHS
Walking 1 Year Hip Score	5.3 +/- 3.0	3.4 +/- 3.4
Sliding Collapse	.91 +/- .46 cm	1.90 +/- .78 cm
Length Discrepancy Mean	1.0 +/- 4 cm R (0-1.9 cm)	1.6 +/- 0.63 cm R (0-3.4 cm)

Mobility Score of Parker and Palmer*

Walking Ability	No Difficulty	Alone with an Assistive Device	With Help from Another Person	Not at All
Able to walk inside house	3	2	1	0
Able to walk outside house	3	2	1	0
Able to go shopping, to a restaurant, or to visit family	3	2	1	0

*The values are given as the number of points assigned for that answer. The maximum possible score is 9 points.

19 mm Sliding Mean??

The Difference

Harty,M. The Calcar Femorale and The Femoral Nec. JBJS 1957
Garden. Structure and Function of The Proximal Femur JBJS 43B 1961

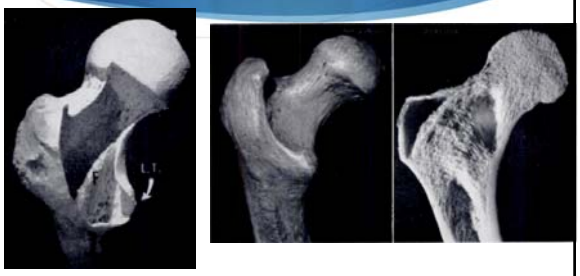

High Risk With Triple Reamer and Thickness of Lateral Wall 20 mm

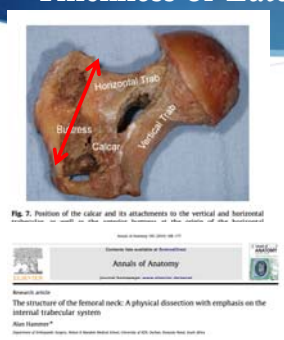

Jbjs2013 Hsu et al

Proximal Femur Metaphysis Most of Fill In Metaphysis

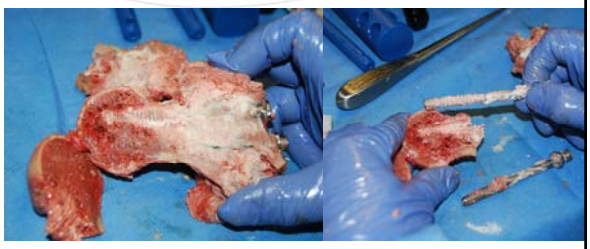

15

Head Is Best Bone

Historical Perspective: Impaction Nails

1939

JEWETT (FL)
JBJS 1941 Vol. 23 (5 cases)

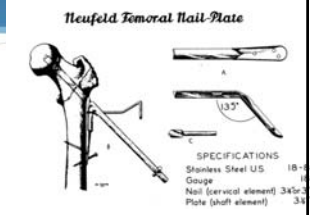

40% Failure With Unstable Fractures:
Medial Penetration
Superior Cut-Out
Plate Breakage

Taylor, Neufeld, Janzen (CA)
JBJS 1944 Vol. 26

Trochanteric Buttress Plates Boyd and Richardson 1949

- Invention of Trochanteric Buttress Technique For Boyd Type III (Reverse Obliquity) By Resident Dr. Richardson

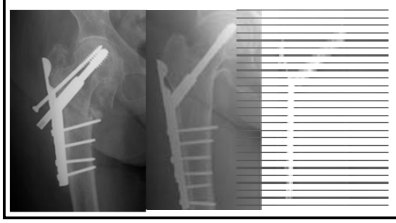

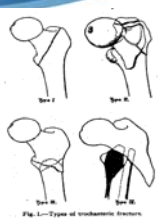

TSP Martre JBJS 2013

Sliding Compression Hip Screw Pohl 1953 Kiel, Germany

A NEW PRINCIPLE IN THE OPERATIVE TREATMENT OF TROCHANTERIC FRACTURES OF THE FEMUR

W. Schumpelick and P. M. Jantzen
J Bone Joint Surg Am. 1955;37:693-698.

We were somewhat alarmed when we observed that the quick telescoping of the fracture fragments sometimes resulted in a relative "lengthening" of the iliac muscles and therewith in a positive Trendelenburg sign. Fortunately, this phenomenon is later compensated.

E. P. Holt 1963 Rotation Not Important?

JBJS

Hip Fractures in the Trochanteric Region: Treatment with a Strong Nail and Early Weight-Bearing: A REPORT OF ONE HUNDRED CASES

- First To Hypothesize No Rotational Stability With Trochanteric Fractures
- Reamed to Size 12.5mm Round Nail
- "All flanges on the nail were eliminated since it seemed unlikely that the proximal fragment of an intertrochanteric fracture could rotate after the fracture was reduced, … No evidence of rotation was seen on lateral roentgenograms in the follow-up of the 100 fractures included in this study."

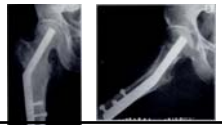

Jensen Classification Effect of Reduction With CHS 1980

- J. S. Jensen Comparative Classification Study. Added Lateral Evaluation of Fracture To Evans Acta Ortho Scand
  - Relates Ability to Reduce Fracture and Secondary Displacement Risk With CHS Device
  - **Anatomic Reduction Both Planes Stable Medial Cortex: No Secondary Displacement**
  - **Non-Anatomic and/or Unstable Fracture: 25-69% Rate of Secondary Displacement**

InterTan Vs. CHS +TSP Matre et al JBJS 2013; 95:200-8

56% of Nails and 51% of Plated Hip Fractures Were Reduced in a Potentially Unstable Position

TABLE E-2 Radiographic Findings

	INTERTAN*	Sliding Hip Screw*	P Value†
Postop. fracture reduction‡			0.25§
Good	147 (44%)	164 (48%)	
Acceptable	141 (43%)	143 (42%)	
Poor	44 (13%)	32 (9%)	
Total	332 (100%)	339 (100%)	

1960-70's Osteotomies For Unstable Pertrochanteric Fractures Discontinued in 1980's

- The desire to increase stability of unstable fracture patterns with proactive valgus oteotomies was poplularized by Dimon and Houston, Sarmiento, Harrington and others in the 1960-70's[28, 29, 105]
- Desjardins AL, Roy A, Paiement G, et al. Unstable intertrochanteric fracture of the femur. A prospective randomised study comparing anatomical reduction and medial displacement osteotomy. *J Bone Joint Surg Br.* 1993;75(3):445-447.
- Dimon JH, Hughston JC. Unstable intertrochanteric fractures of the hip. *J Bone Joint Surg Am.* 1967;49(3):440-450.
- Harrington KD, Johnston JO. The management of comminuted unstable intertrochanteric fractures. *J Bone Joint Surg Am.* 1973;55(7):1367-1376.
- Sarmiento A. Intertochanteric fractures fo the femur: 150-degree angle nail plate fixation and early rehabilitation: a preliminary report of 100 cases. *J Bone Joint Surg Am.* 1963;45(4):706-722.
- Sarmiento A, Williams EM. The unstable intertrochanteric fracture: treatment with a valgus osteotomy and I-beam nail-plate. A preliminary report of one hundred cases. *J Bone Joint Surg Am.* 1970;52(7):1309-1318.

31A CHS Treated Rotational Instability Failures

Lustenberger, Bekic, et al 1995
Unfallchirug 98(10):514-7
22 Years After HOLT

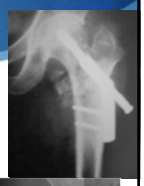

1. Lateral Impaction (Sliding) ($P < 0.001$).
2. Cut-out
3. Delayed Union
4. Varus Angulation

"We Conclude That Rotational Instability of a Gliding Implant System Is a Severe Complication in the Treatment of Trochanteric fractures."

Lateral Wall Fracture

Y. Gotfried,
CORR 2004, 425:82-86

Fracture of The Lateral Wall =Prolonged Morbidity

Fracture Around Implant From Defect Induced by Rotational Stress

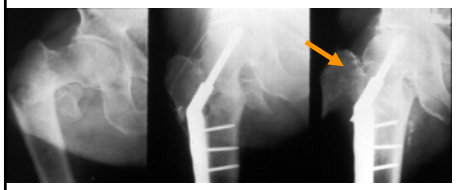

- Collapse Of Fracture Results In Loss of Lower Extremity Shortening And Abductor Weakness Note Fracture of Lateral Wall

Instability With CHS Moroni et al 2004 Italy

- Moroni, Faldini, Pergreffi, Giannini. Clin Orthop Rel Res 2004, Aug;(425):87-92
- **Varus Collapse CHS vs None With HA CHS**
- Improved Functional Result With No Collapse (Harris Hip Score)
- Moroni et al JBJS 2005
  - Single Screw Compression Plate
  - HA Coated External Fixation Pin
  - **Average Migration 4 mm Of Screw In Head In Cases Which Healed With Progression of Varus of 6 Degrees Post Op In CHS Group**

Nov-16 25

Implant Etiology for Instability With CHS Im et al 2005

- 66 Patients With 31-A1 Stable Fractures.
- Ten (15.1%) Were Noted To Lose Reduction While Developing Excessive Medialization Of The Femoral Shaft In The Postoperative Period.
- Of These Patients, A Fracture With Displacement Of The Lateral Cortex Occurred In All Cases Within 4 Weeks After Surgery.
- A Significant Difference In Mobility Score Was Noted Between Patients Who Lost Fracture Stability After The Operation And Those Who Did Not

Im GI, Shin YW, Song YJ. Potentially unstable intertrochanteric fractures. J Orthop Trauma. 2005;19:5–9.

Rotational Instability Caused Cut-Out??

ORIGINAL ARTICLE

JOT 18:36:361-368, 2004

A Laboratory Model to Evaluate Cutout Resistance of Implants for Pertrochanteric Fracture Fixation

Mark B. Summers, MS, Christoph Roth, MS,† H. Hall, MS,† Benjamin C. C. Kam, MD,‡ Larry W. Ehmke, MS,* James C. Krieg, MD,* Steven M. Madey, MD,* and Michael Bottlang, PhD**

Ehmke, L.W., et al., Lag screws for hip fracture fixation: Evaluation of migration resistance under simulated walking. J Orthop Res, 2005. 23(6): p. 1329-35.

- The Degree Of Varus Collapse (8.5+/-7.7 Degrees) And Rotation (7.2+/-6.4 Degrees) In Cadaveric Specimens Were Comparable To That In Surrogate Specimens
- Clinically Realistic Multiplanar Loading Vectors Significantly Affects Implant Migration, And Therefore Should Be Considered When Evaluating The Fixation Strength Of Hip Screw Implants.

Implant Etiology for Instability With CHS? Im et al 2005

- 66 Patients With 31-A1 Stable Fractures.
- Ten (15.1%) Were Noted To Lose Reduction While Developing Excessive Medialization Of The Femoral Shaft In The Postoperative Period.
- **Of These Patients, A Fracture With Displacement Of The Lateral Cortex Occurred In All Cases Within 4 Weeks After Surgery.**
- A Significant Difference In Mobility Score Was Noted Between Patients Who Lost Fracture Stability After The Operation And Those Who Did Not

Im GI, Shin YW, Song YJ. Potentially unstable intertrochanteric fractures. J Orthop Trauma. 2005;19:5–9.

PCCP Gotfreid

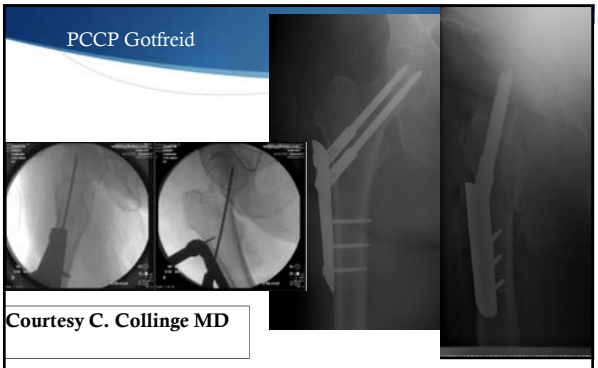

Courtesy C. Collinge MD

Laufer, Y., et al., Functional recovery following pertrochanteric hip fractures fixated with the Dynamic Hip Screw vs. the percutaneous compression plate. Scientific World Journal, 2005

Integrity of the Lateral Femoral Wall in Intertrochanteric Hip Fractures: An Important Predictor of a Re-operation 2007

- 74% of Lateral Wall Fractures Occur During Surgery
- Fracture Lateral Wall Causes a Re-Op Rate of 22%
- 'IT Fractures With Lateral Wall Fractures Should Not Be Treated With Sliding Compression Hip-Screw Devices

Palm, Jacobsen Sonne-Holm and Gebuhr: Hip Fracture Study Group Denmark, JBJS 89-A, 470-475, 2007

Gotfried PCCP Less Iatrogenic Lateral Wall Failures 2011

- There was an overall lateral wall fracture incidence of **20% in the SHS group versus 1.4% in the PCCP group** (P < 0.01). For the unstable 31A2 fracture types, there was a **lateral wall fracture incidence of 29.8% in the SHS group versus 1.9% in the PCCP group (P < 0.01).**
- Langford J, Pillai G, Ugliailoro AD, et al. Perioperative lateral trochanteric wall fractures: sliding hip screw versus percutaneous compression plate for intertrochanteric hip fractures. J Orthop Trauma. 2011;25: 191–195.

Problem Solved? Don't Use A CHS

- Palm H, Lysén C, Krasheninnikoff M, Holck K, Jacobsen S, Gebuhr P. Intra- medullary nailing appears superior in pertrochanteric hip fractures with a detached greater trochanter. Acta Orthop 2011; 82 (2): 166-70.
- Booplalan PR; Oh JK; Kim TY; Oh CW; Cho JW; Shon WY. Incidence and radiologic outcome of intraoperative lateral wall fractures in OTA 31A1 and A2 fractures treated with cephalomedullary Nailing. J Orthop Trauma 2012. 26(11):638-42.

Next Generation SHS?
3 Screw Sliding Fixation In Head

Linear Compression Device

SUPPLEMENT ARTICLE

What Makes an Intertrochanteric Fracture Unstable in 2015? Does the Lateral Wall Play a Role in the Decision Matrix?

Akhil A. Tawari, MS, Harish Kempegowda, MS, Michael Suk, MD, and Daniel S. Horwitz, MD

Summary: Intertrochanteric (IT) fractures pose a tremendous burden to the healthcare system. Although consistently good results are obtained while treating stable IT fractures, treatment failure rates with unstable fractures are much higher. Clearly, not better, it is imperative to identify unstable patterns. Strikingly, the existing unstable classification systems differentiate between the stable patterns (fracture with posteromedial comminution, reverse oblique, IT with subtrochanteric extension) and the recently added fracture patterns (IT fractures with avulsed greater trochanter and lateral wall breach) qualify as unstable IT fractures; however, the list is certainly not exhaustive. Disruption of lateral wall concrete an IT fracture into a reverse oblique fracture equivalent and should be given a strong consideration in the decision matrix.

Key Words: unstable intertrochanteric fracture, lateral wall fracture

(*J Orthop Trauma* 2015;29:S4–S9)

INTRODUCTION

Intertrochanteric (IT) fractures are one of the most common types of fracture, with a growing incidence subsequent to increasing longevity of the population.[1] They comprise approximately half of the annual 258,000 hip fractures occurring in the United States.[2] IT fractures, especially unstable ones, are a tremendous burden to the healthcare system. Achieving a stable fixation and ensuring a faster rehabilitation to preinjury levels is the primary objective while managing these fractures; consequently, multiple implants and their various modifications have been introduced in the last 3–4 decades.[3] Although consistently good results are obtained while treating stable IT fractures, treatment failure rates with unstable fractures are much higher.[4,5] Unstable IT fractures' propensity to drift into varus and have excessive collapse can result in pain, functional deficit, and implant failure.

Patient characteristics (age, comorbidities, and bone density) and fracture patterns are beyond the treating surgeon's control; however, understanding fracture geometry, choosing an appropriate implant, achieving adequate reduction, and proper placement of the implant are all surgeon-dependent factors. A proper understanding of the fracture personality and the ability to predict its behavior after fixation are crucial for a satisfactory outcome. The first step toward management is to differentiate between stable and unstable patterns, and multiple classification systems have attempted to differentiate between the two.[6–8] In simple terms, a stable pattern is one that can be reduced and fixated effectively, adequate reduction and fixation, and prognosis includes 2-part IT fractures with an intact posteromedial buttress. An intramedullary (IM) device and sliding hip screw (SHS) are both appropriate treatment options with similar results. However, an unstable pattern shows a tendency to collapse even after adequate reduction and fixation. Currently, the conventionally classified unstable patterns (fracture with posteromedial comminution, reverse oblique, and IT with subtrochanteric extension) and the recently added fracture patterns (IT fractures with detached greater trochanter and lateral wall breach) qualify as unstable IT fractures; however, the list is certainly not complete.[9]

The SHS is an acceptable implant for stable fracture configuration, with literature showing SHS giving equivalent results in comparison with the IM device.[10] However, the failure rates of SHS are much higher in the presence of unstable fracture patterns, for which IM devices are the current implant of choice.[11] A comprehensive radiologic evaluation comprising of an anteroposterior view, lateral view, and trochanteric view of the hip should be obtained in all patients before any intervention. In the presence of an unusual or a highly comminuted fracture, CT scan with 3-dimensional reconstruction can aid in better assessment of the fracture pattern.[9] Instability may be detected intraoperatively, and then the treating surgeon has to be prepared to alter the management plans for a suitable outcome.

CONVENTIONAL UNSTABLE IT

Posteromedial Component

The calcar femoralе is a vertically oriented thickened strip of bone that radiorthrus the stress from the posteromedial aspect of the femoral neck to the anterior and lateral supports.[12] Consequently, disruption of the calcar femoralе renders the fracture susceptible to collapse with axial loading and may result in weakened abductors and poor outcome.[13] Evans,[14] in 1949, first acknowledged the importance of reestablishing the posteromedial cortical continuity to convert an

Accepted for publication January 9, 2015.

From the Department of Orthopaedic Surgery, Geisinger Medical Center, Danville, PA.

The authors report no conflict of interest.

Written of patient consent granted by IRB for retrospective chart review.

Reprints: Daniel S. Horwitz, MD, Department of Orthopaedic Surgery, Geisinger Medical Center, 100 N. Academy Avenue, Danville, PA 17822-2130 (e-mail: dshorwitz@geisinger.edu).

Copyright © 2015 Wolters Kluwer Health, Inc. All rights reserved.

Lateral Wall Fragments

- External Rotation: Stable With Nail
- Cephalad Retraction: Reduce & Fix
- Lateral Wall Failure: Nail or Trochanteric Buttress Fixation

Conclusions

- Anteromedial Component Reduction Critical
- Select the Implant:
  - Best Fatigue Life
  - Stability in All Planes in Head and Shaft
- Recognize The Lateral Wall Problem
  - Prevention with Modern Implant
    - ORIF Buttress Plate
    - Cephalomedullary Nail Bypass
- Recognize Bone Quality Insufficiency