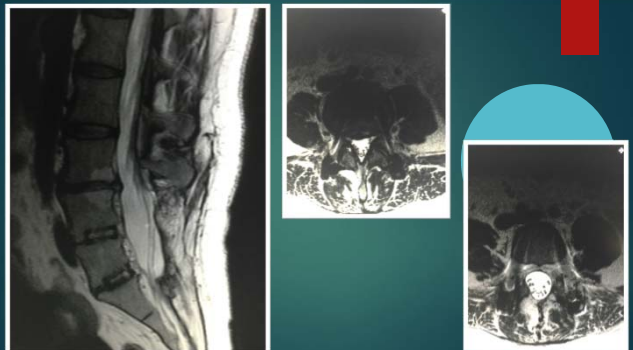


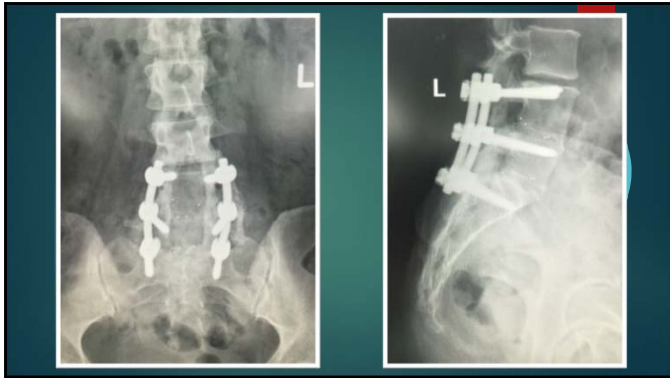OLIF FOR REVISIONS

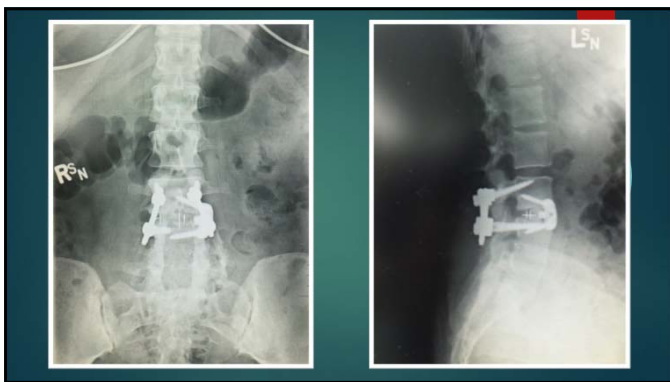RICHARD HYNES, MD
THE BACK CENTER
MELBOURNE, FL
APRIL 28, 2016

Patient 1 – L3/L4 ASD

- ▶ 41 y/o Female with prior history of TLIF L4/S1
- ▶ Adjacent Level Degeneration L3/L4
- ▶ Surgical Plan – L3/L4 OLIF Using Pivox and Posterior Fusion with Decompression and Cortical Screw Fixation





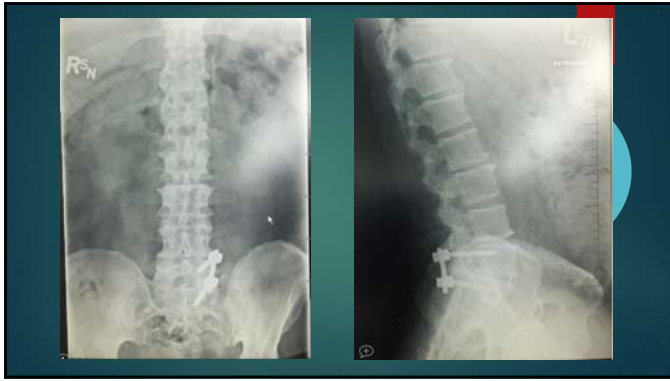

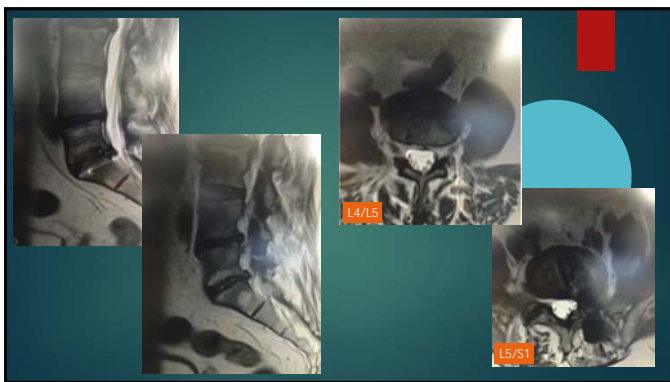
Patient 2 - PAP Patient (Pseudo)

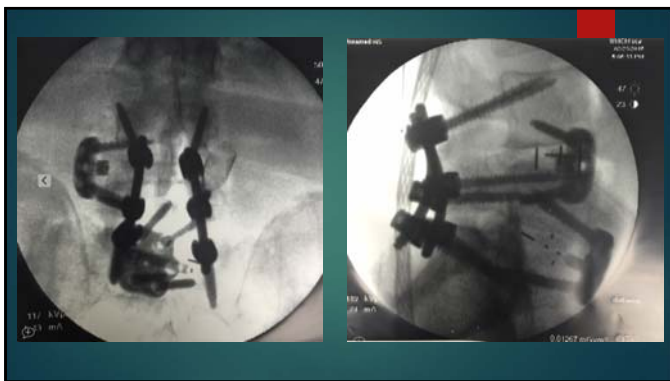
- ▶ 62 Y/O Male
- ▶ History of TLIF at L5/S1 in Northeast
- ▶ Pseudarthrosis at L5/S1
- ▶ Adjacent Segment Disease at L4/L5

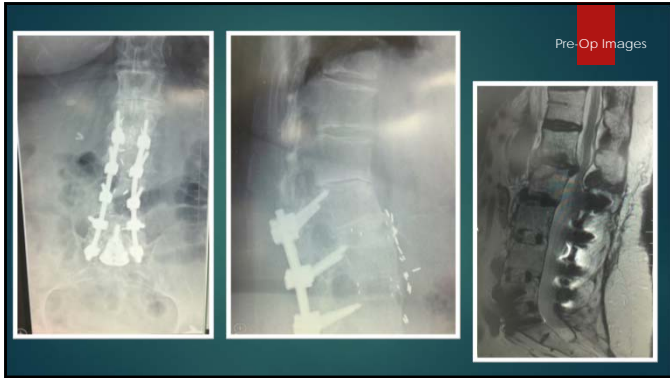Time Lost due
to flipping
twice
2+ Hours

- ▶ Plan
- ▶ Removal of Posterior Hardware
- ▶ Removal of TLIF Cage Using OLIF51 Approach
- ▶ OLIF25 at L4/L5
- ▶ Revision Posterior Instrumentation



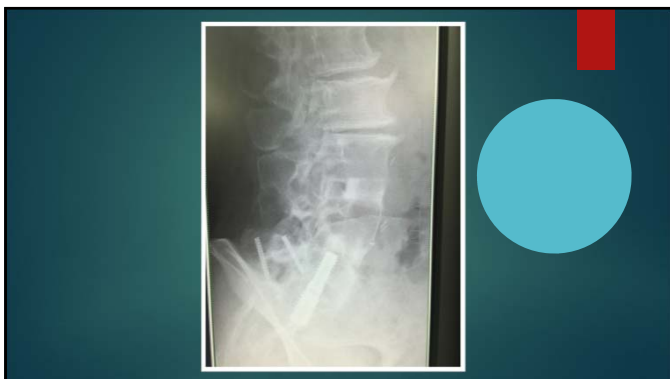

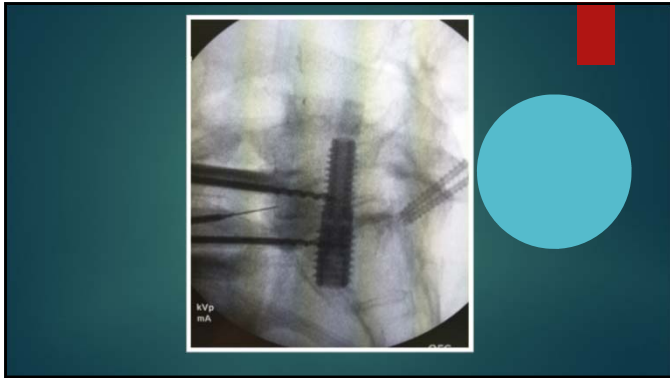



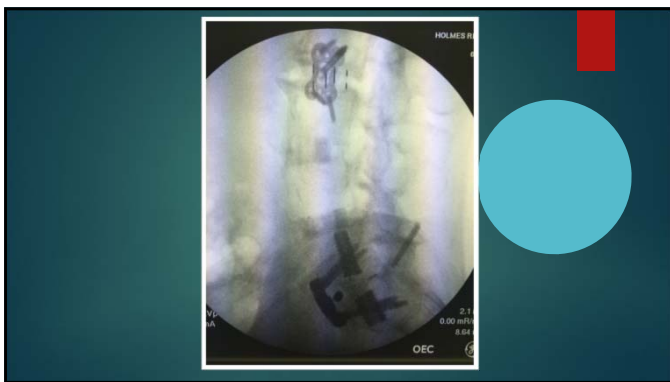
Patient 3 – L5/S1

- ▶ 41 y/o Female with prior history of AXIALIF L5/S1 and ALIF with allograft L3/L5
- ▶ Pseudoarthrosis – L5/S1
- ▶ Adjacent Segment Disease – L2/L3
- ▶ Surgical Plan – Revision OLIF L5/S1 with add on OLIF – L2/L3







Patient 3 – L5/S1

- ▶ 41 y/o Female with prior history of AXIALIF L5/S1 and ALIF with allograft L3/L5
- ▶ Pseudoarthrosis – L5/S1
- ▶ Adjacent Segment Disease – L2/L3
- ▶ Surgical Plan – Revision OLIF L5/S1 with add on OLIF – L2/L3

