


MAYO CLINIC



HUMERAL SHAFT FRACTURES: ORIF, IMN, NONOP...What to do?

Trauma 101: Fracture Care for the Community Orthopedist

William W. Cross III, MD
Assistant Professor
Vice Chair, Department of Orthopedic Surgery
Chair, Division of Community Orthopedic Surgery
Division of Orthopedic Trauma
Rochester, MN

DISCLOSURES

- I have no disclosures

MAYO CLINIC

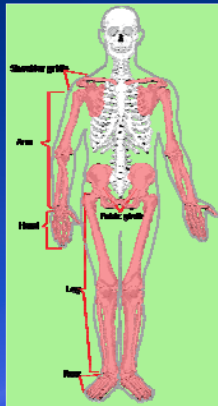
GOALS AND OBJECTIVES

- Why the humerus is unique
- Principles of nonoperative treatment
- Surgical indications
- Pros and cons of plating and nailing
- How to manage radial nerve injury

MAYO CLINIC

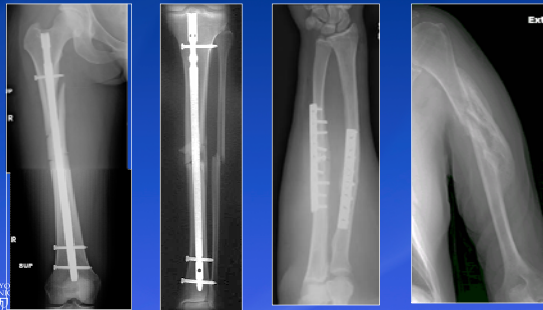HUMERAL SHAFT FRACTURES

- Different from other diaphyseal fractures
- Acceptable deformity much greater
 - Shoulder ROM
- Leg length inequality \neq arm length inequality



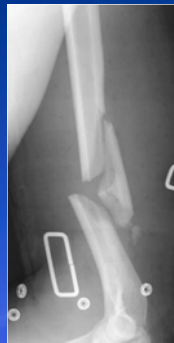HUMERAL SHAFT FRACTURES

NON-OP WORKS!





NONOPERATIVE TREATMENT

- Hanging Arm Cast
- Coaptation Splint
- Velpeau
- Abduction Brace
- **Functional Brace**



TREATMENT PROTOCOL

- Minimal reduction
- Over lateral deltoid
- Upright position
- Until comfortable







FUNCTIONAL BRACE

- Prefabricated vs. custom
- Snug as tolerated
- Add collar and cuff
- Encourage early motion




FUNCTIONAL BRACE



FUNCTIONAL BRACING


Balfour et al, JBJS 1982
Zagorski, et al, JBJS 1988
Sarmiento et al, JBJS (Br) 1990
Wallny et al, JOT, 1997
Sarmiento et al, JBJS 2000


UNION RATES: 94-100%

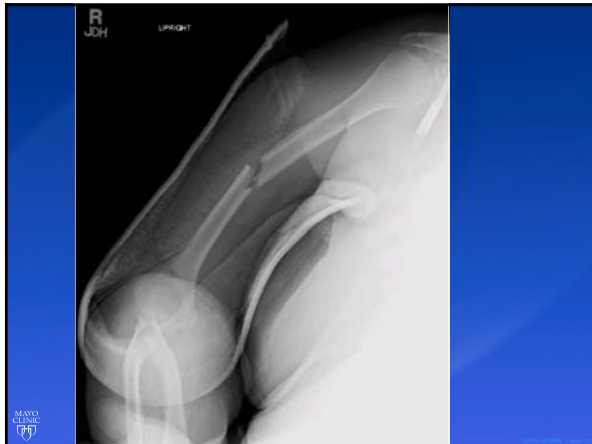

Words of Wisdom

- Apply coaptation splint in ER
 - May check ONE x-ray
 - Let hang out for a week or so
- Change to functional brace
 - May check ONE x-ray
- See back q2-3 weeks for imaging eval
- Must Must let gravity do its job
- Watch out for varus-producing anatomy







Study Name	Study Position	Image	Image	Image
10-Feb-2012 13:21:00	R Humerus Upright RAD	0	FHL	MCR
10-Feb-2012 13:21:00	R Humerus Upright...	RAD	8	FHL MCR
10-Feb-2012 12:20:00	R Humerus Upright...	RAD	2	FHL MCR
10-Feb-2012 11:00:00	R Humerus Upright...	RAD	2	FHL MCR
30-Jan-2012 10:22:00	R Humerus Upright...	RAD	2	FHL MCR
24-Jan-2012 18:46:00	Fluoro Assistan...	RAD	ARC	FHL MCR
24-Jan-2012 18:25:00	R Humerus Upright...	RAD	3	FHL MCR
24-Jan-2012 14:42:00	R Humerus 2vw...	RAD	ARC	FHL MCR


10 Feb 2012 13:21:00
Se: 0001 Se: 0002 Se: 0003 Se: 0004 Se: 0005 Se: 0006 Se: 0007

HUMERAL SHAFT FRACTURES

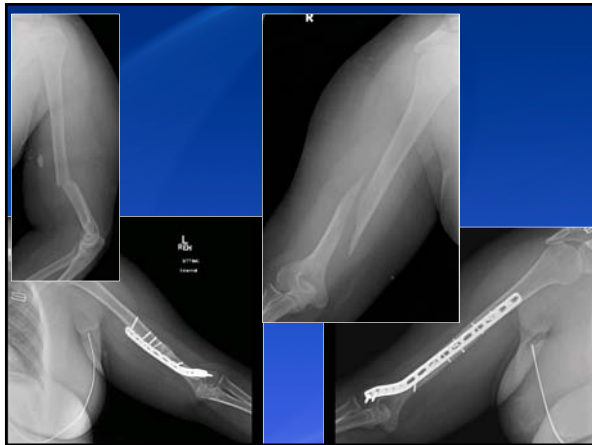
- Almost all patients have some minor deformity and shortening
- **Acceptable Healing**
 - 20° anterior angulation
 - 20° varus angulation
 - 2.5 cm shortening
- 40% have some loss of shoulder ROM
- 25% have some loss of elbow ROM

Sarmiento et al. JBJS 82A: 478, 2000

OPERATIVE INDICATIONS




- OPEN FRACTURES
 - Significant soft tissue injury that precludes bracing
- FLOATING ELBOW
- VASCULAR INJURY
- POLYTRAUMA
- PATHOLOGIC FRACTURES
- BRACHIAL PLEXOPATHY
- INTRA-ARTICULAR EXTENSION
- FAILURE OF NON-OPERATIVE MANAGEMENT



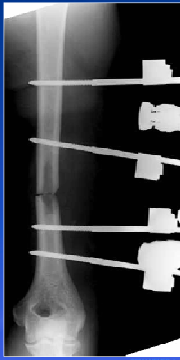
OPERATIVE TREATMENT

- ORIF with plates
- Antegrade nails
- Retrograde nails
- Flexible nails
- Flexible locked nails
- External fixation



EXTERNAL FIXATION


- Neurologic risk
 - Radial nerve
- Elbow and shoulder stiffness
- Pin tract infections
- Malunion
- Rarely used definitively



MAYO CLINIC

EXTERNAL FIXATION

- Massive soft tissue injury/contamination
- Vascular injury
- Severe polytrauma



MAYO CLINIC

ANTEGRADE NAILING

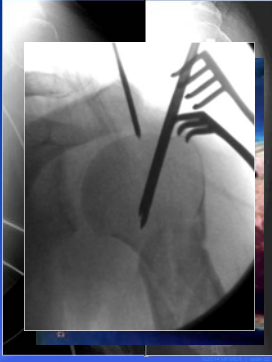
- Closed technique
- Load sharing
- Mechanical advantages
- Consider in:
 - Pathologic fx
 - Segmental fx
 - Polytrauma
 - Osteoporosis



MAYO CLINIC

ANTEGRADE NAILING

- Technical factors important:
 - Countersink nail
 - No fx distraction
 - Minimize cuff injury
 - Rotator interval
 - **Medial start point**
 - Avoid radial n. injury
 - Anatomic reduction or expose

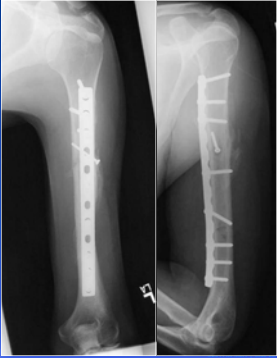


MAYO CLINIC

OPEN REDUCTION INTERNAL FIXATION

GOLD STANDARD


- Anatomic reduction/ compression or bridging
- High union rates (96%)
- Exposures extensile
- Allows radial nerve protection
- Early weight bearing



MAYO CLINIC

OPEN REDUCTION INTERNAL FIXATION

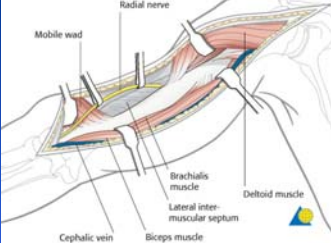
- Plate size:
 - 4.5 broad LC-DCP
 - Historical
 - **4.5 narrow LC-DCP**
 - **Current**
 - 3.5 LC-DCP
 - Future?
- Over-contour posterior plate
- **No shorties!!**
- Locking screws typically not necessary



MAYO CLINIC

ANTEROLATERAL APPROACH

- Extensile
 - DP proximally
- “Cannot access distal quarter”
- Retract biceps medially
- Elevate brachialis

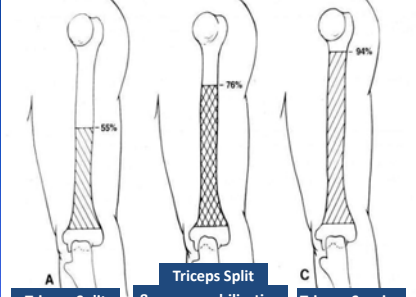


MAYO CLINIC

Alternative Operative Exposures of the Posterior Aspect of the Humeral Diaphysis

WITH REFERENCE TO THE RADIAL NERVE*

BY MICHELLE GERWIN, M.D., ROBERT N. HOTCHKISS, M.D., AND ANDREW J. WEILAND, M.D., NEW YORK, N.Y.
Investigation performed at The Hospital for Special Surgery, New York City

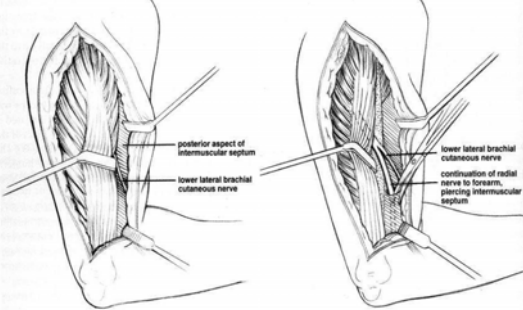


MAYO CLINIC

Alternative Operative Exposures of the Posterior Aspect of the Humeral Diaphysis

WITH REFERENCE TO THE RADIAL NERVE*

BY MICHELLE GERWIN, M.D., ROBERT N. HOTCHKISS, M.D., AND ANDREW J. WEILAND, M.D., NEW YORK, N.Y.
Investigation performed at The Hospital for Special Surgery, New York City



MAYO CLINIC

NAIL VS PLATE: PRT's

Changulani et al., SICOT 2006
 Chapman et al., JOT 2000
 McCormack et al., JBJS[Br] 2000
 Bolano et al., AAOS 1995

	n	Nonunion	Infection	Shoulder Pain	Radial Nerve	Reoperations
Plate	105	8	6	1	2	8
Nail	87	11	2	20	5	17

MAYO CLINIC

RADIAL NERVE PALSY? CLOSED FRACTURE

Pollack et al, JBJS, 1981

- 24 Radial Nerve Palsies
- Incidence: 11%
- All Resolved Eventually
- 8% (2) Required Late Exploration

RECOMMENDATION:
 Don't need to explore early
 Spontaneous recovery rate 90-95%

MAYO CLINIC

RADIAL NERVE PALSY? OPEN FRACTURE

Foster et al, JHS, 1993

- 14 Patients with open fractures
- 64% (9) with nerve injury interposed or lacerated


RECOMMENDATION:
 Explore and ORIF

MAYO CLINIC

CLOSED FRACTURE
Radial n palsy after reduction
Bostman et al., Acta Orthop Scand 1986


- 59 patients : immediate radial nerve palsy
 - Useful recovery: 46/59 (88 %)
- 16 patients: secondary radial nerve palsy
 - Useful recovery: 14/16 (87.5%)

RECOMMENDATION:
Exploration not required
(More controversial)




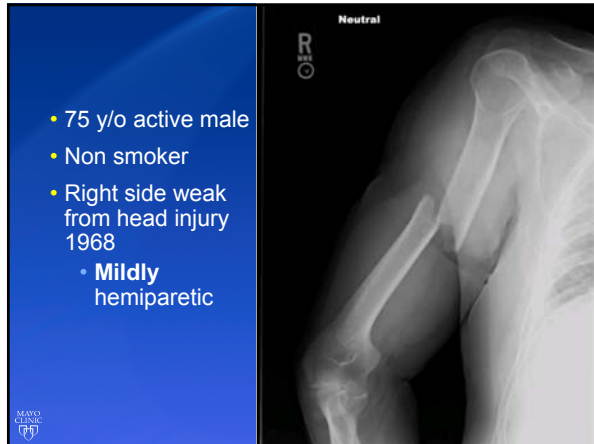RADIAL NERVE RECOVERY

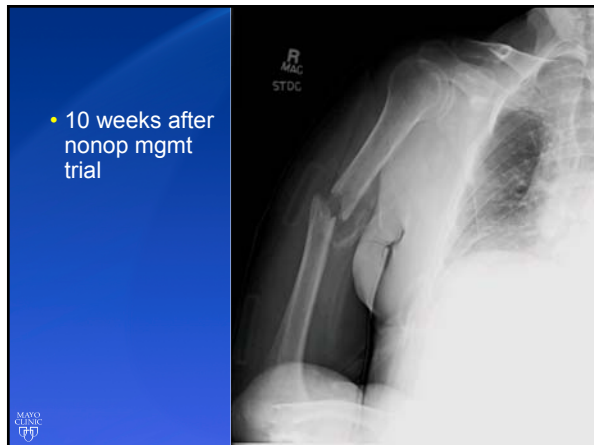- Average time to first sign of recovery: 7 weeks
 - But may take as long as 6 months!
- Average time to complete recovery: 6 months
 - But may take as long as 21 months!

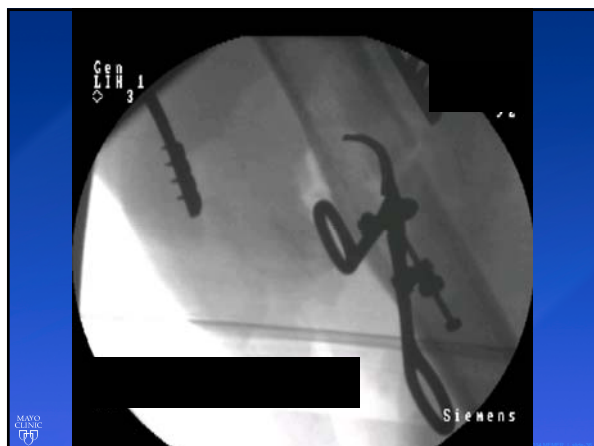

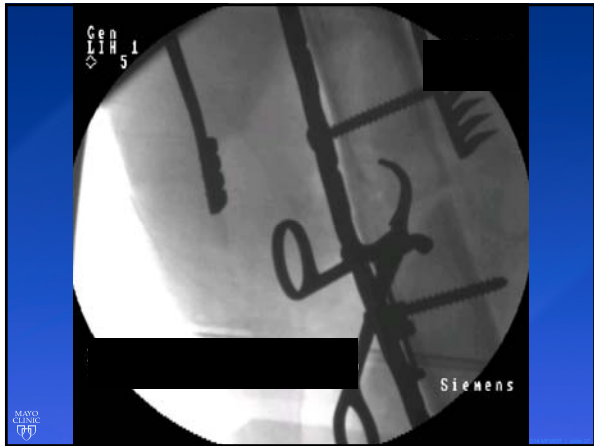Case example

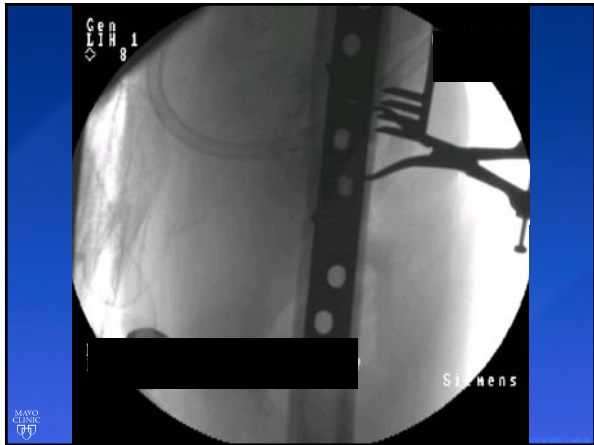


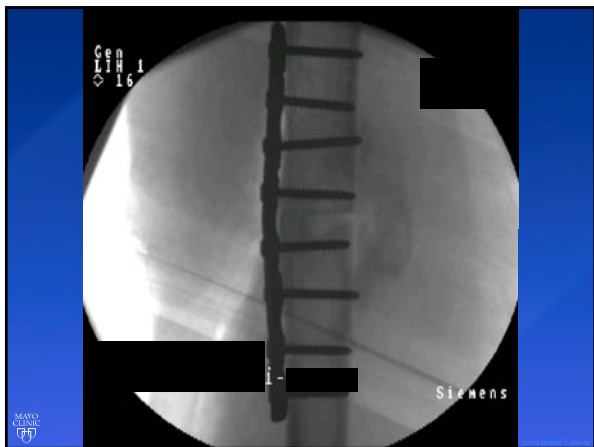
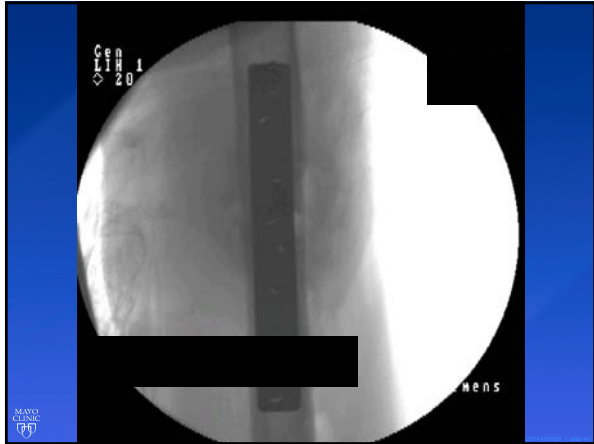


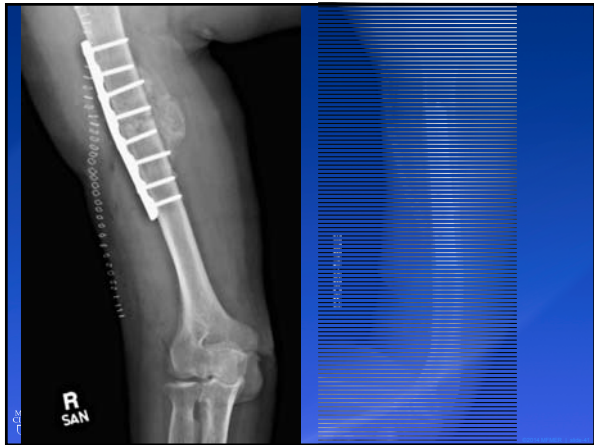


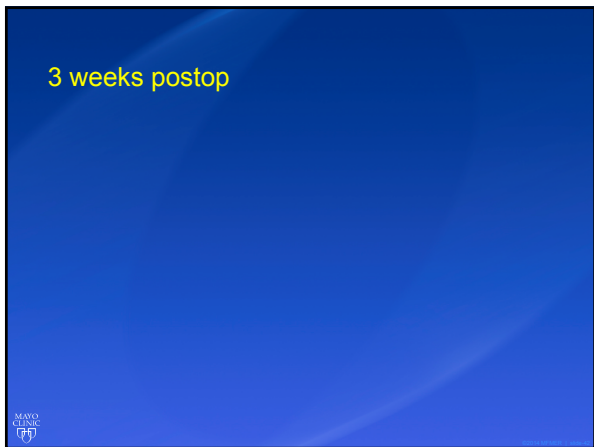


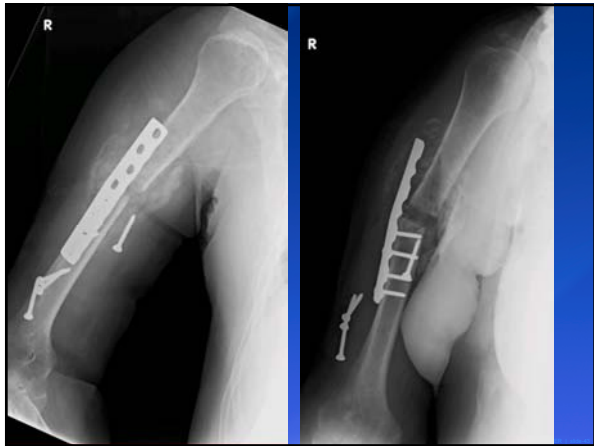


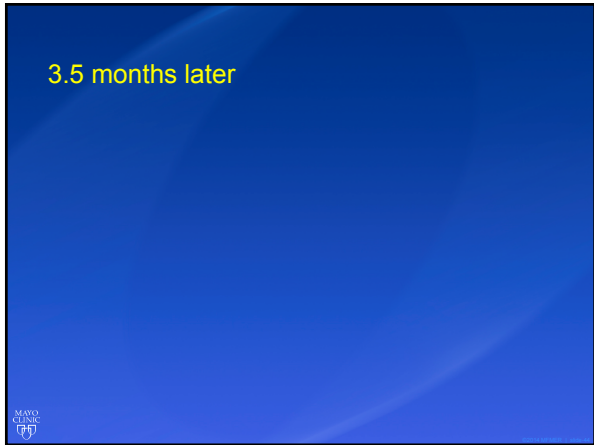


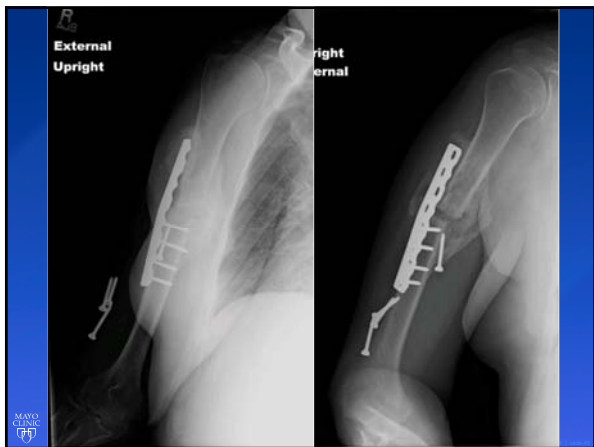




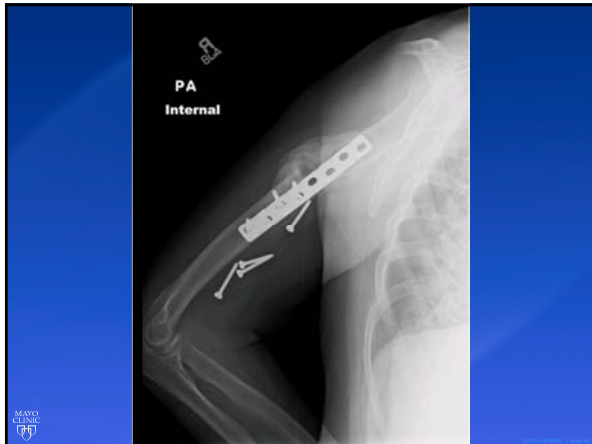


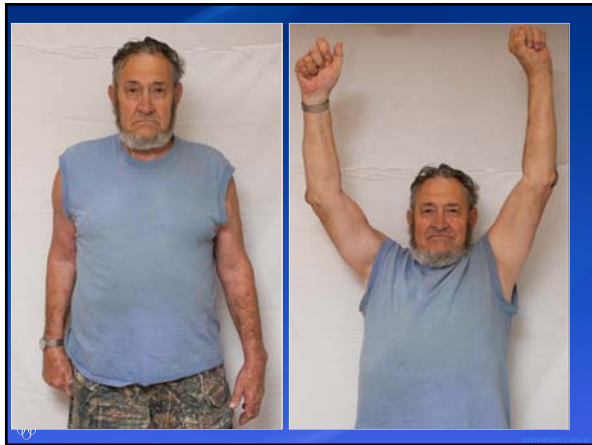








My Practice: Humeral Shaft Fractures

- Patient history and desires
- Trial of nonop management
- Not 3 months!
 - Pull trigger at 6 weeks
- Plate is my implant preference (4.5 narrow, non-locked)
 - Posterolateral approach (Gerwin-Hotchkiss)
- Nailing-pendulum may swing back in favor
 - Straight nails

STANFORD
UNIVERSITY
MEDICAL CENTER

SUMMARY

- Closed treatment in most injuries
 - Early functional brace
- Know multiple treatment options
 - Customize care based on pt/injury factors
- Know exposures
- Plates work well – go long or go home!
- Radial nerve injury ≠ surgery
- Technique, technique, technique!