

Lateral Patella Dislocation:
Trauma 101 Knee Symposium

Brian Grawe, MD
Assistant Professor
Orthopaedics & Sports Medicine
4/28/2016



Brian Grawe, MD
Assistant Professor



Phone Number: 513-558-4516

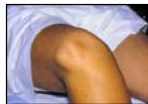Email: grawebn@ucmail.uc.edu

I HAVE NO DISCLOSURES or COI



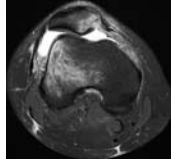
Outline

- Background
- Anatomy
- Evaluation
- Treatment
 - Algorithm
 - Proximal vs. Distal vs. Other
 - Outcomes
- Summary



Background

- Epidemiology
 - 3% of all knee injuries
 - Annual incidence 5.8/100K
 - Young (10-16 yo); female
- Recurrence
 - **15-80%**
 - (variable)(the next horizon)**
 - >50% after second dislocation



... This is a multifactorial problem
 ... Patient population is heterogeneous

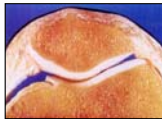JBS 2016



Anatomy

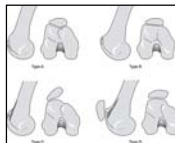
Patella

- Sesamoid bone
- Improve lever arm
- Thickest cartilage (7mm)
- Lateral facet larger
- Medial & odd facet (flexion)



Trochlea

- Deepens distally
- Dysplasia



Engagement at 20-30°

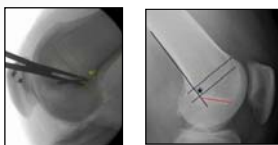
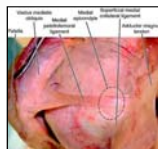
JKS 2015



Anatomy

Medial patellofemoral ligament (MPFL)

- Layer 2 (think btw layers 2 & 3)
- ~ Adductor tubercle / ~ epicondyle
- Upper 2/3 patella / quadriceps tendon (broad)
- 1.3 cm thick; 58 mm long
- 208 N tensile strength
- 60% of lateral restraint (1st 30°)
- Loosens in flexion
- ISOMETRIC STRUCTURE



Orthopedics 2008



Evaluation: Clinical (pearls)

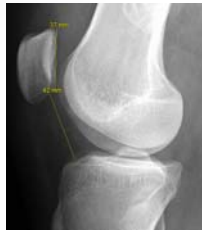- | | |
|--|--|
| <ul style="list-style-type: none">• History<ul style="list-style-type: none">- Previous episode?- Previous tx?- Traumatic?- Need for reduction?- Skeletal maturity?- Family Hx? | <ul style="list-style-type: none">• Exam<ul style="list-style-type: none">- Beighton score- Basset sign (TTP)- J-sign (tracking)- Lateral glide >3<ul style="list-style-type: none">• Apprehensive• Contralateral side- Moving apprehension |
|--|--|



Evaluation: Diagnostic Imaging

Radiographs

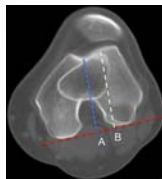
- > Standard series
- > Long-leg (coronal alignment?)
- True lateral 30°
 - > Trochlear morphology
 - > Height (Caton-Deschamps)
 - > OA
- Merchant
 - > Morphology
 - > Tilt
 - > Subluxation
 - > OA



Evaluation: Diagnostic Imaging

CT Scan

- Trochlear morphology
- Femoral/tibial torsion
- CD ratio
- TT-TG ratio
 - > Gold standard (?)
 - > Normal = 8-10mm (*Knee* 2006)
 - > ≥ 20 mm at risk (*KSSA* 2009)
- TT-PCL, TT-TG/PW, TT-TG/TW (?)
 - > *AJSM* 2016



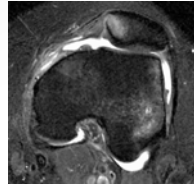
JBS 2016



Evaluation: Diagnostic Imaging

MRI

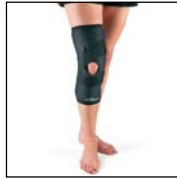- "My gold standard"
- Soft-tissue restraints
 - Femoral side most common
- Chondral surfaces
 - Loose body
- Bone bruises
- CD/TT-TG
 - ... careful AJSM 2013
 - ... (3-4 mm)



Treatment Options: Non-operative

FIRST TIME DISLOCATOR

- RTC JBJS 2008
- Physical Therapy
 - VMO / gluteus / proprioception
- Brace
 - Hinged or lateral stabilizer
 - McConnell tape



... But is this really the best option?
 ➢ Improved understanding of anatomy!
 ➢ Better techniques!
 ➢ More reliable fixation!
 ➢ Atkin et al AJSM 2000 55% did not return to sport!



Treatment Options: MPFL Reconstruction

Pearls

- Understand the anatomy
- Understand your fixation
- Understand principles of graft
- Understand how and why you can get it wrong!

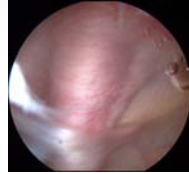
➢ Only proximal re-alignment procedure to be discussed
 ➢ Repair has 28% failure (Mayo AJSM 2010)



Treatment Options: MPFL Reconstruction

Pearls

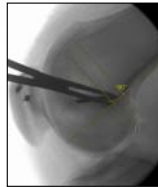- Anatomy
 - Layers 2 & 3 / not in the joint
- Fixation
 - Secure / avoid patella fracture
- Graft
 - Allo v auto... not bigger than 6
 - Isometric... 30 v 45 v 60



Treatment Options: MPFL Reconstruction

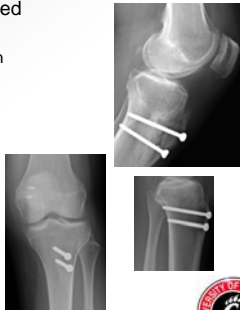Pearls

- Understand how and why you can get it wrong!
- Femoral tunnel is key
 - Anisometric = graft laxity
 - Proximal = flexion loss, ant knee pain
- Do not over-tension
 - Source of pain / dysfunction
 - 2 quadrants post-op
- Results
 - 80%-96% good – excellent (JBJS 2016)
 - 84% RTP, 1% recurrence, 4% apprehensive (AJSM 2016)



Treatment Options: TTO

- Selected plane individualized
 - Anterior, medial, AMZ, distal
 - Alta vs external tibial rotation
- Ø skeletally immature
- CD
 - > 1.4
- TT-TG
 - 15 mm or 20 mm
- Can unload chondrosis



Treatment Options: Other

Femoral derotational osteotomy

- Excessive femoral anteversion
- Pain & instability
- > 20° cut-off
- CT if suspected

Trochleoplasty

- 85% of pts with recurrent instability have some level of dysplasia (KSS7A 1994)
- Indications still being defined



Lateral Patellar Dislocation: Summary

- Know your patient
 - Ligamentous laxity, skeletal age, trochlear dysplasia, alta
- Know your anatomy
 - Use C-arm in the OR
 - Femoral tunnel position is key
- Surgical techniques are evolving
 - Ok to be aggressive with surgery
- Know potential complications and how to avoid
 - Patella fractures
 - Graft isometry



END



Thank you!
Questions / Comments