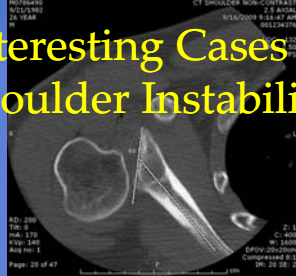


Interesting Cases in Shoulder Instability




CT SHOULDER NON-CONTRAST
2.5 AXIAL
N/AZ0009 9:25:47 AM
001234276

AD: 200
FD: 0
HA: 179
FOV: 340
Alg no: 1
Page: 23 of 47

Z: 1
C: 400
W: 2000
ENOV: 20x20um
Compared: R.L.
DR: 20 SE: 2

Paul M Sethi, MD
Greenwich CT
November 2015

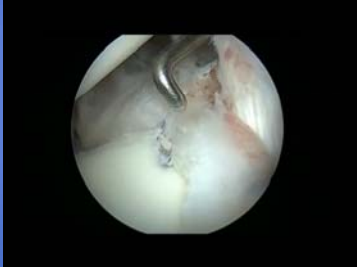

- **John Costouros**
◦ Rhodes Scholar
- **Nikhil Verma**
◦ Bulls, White Sox



1st case. Warm Up

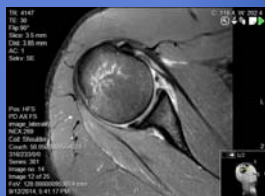Repair, Debride, Tenodesis...



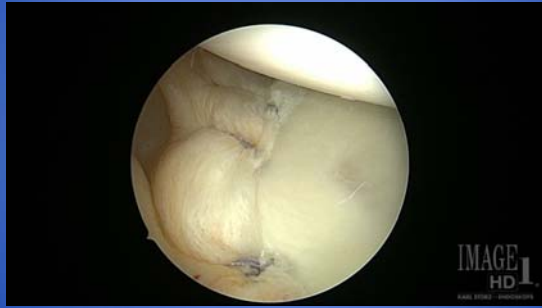Next Case

20 male. D1 Football. RB

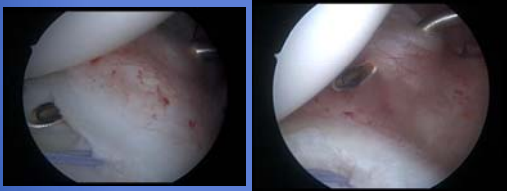
- 2 dislocations in season
- Chooses medical redshirt (missed 5 games at this point)
- Not Hyperlax.



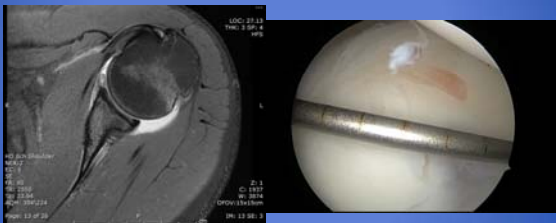
Front Side Pearls and Comments



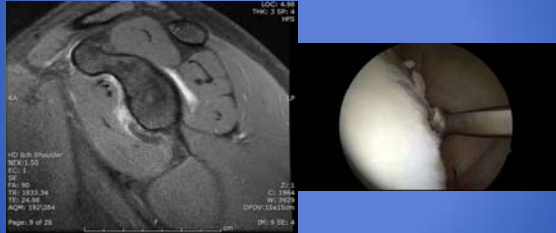
Does a posterior inferior anchor matter ?



Does Hill Sachs Matter




Does ALPSA Change Anything?



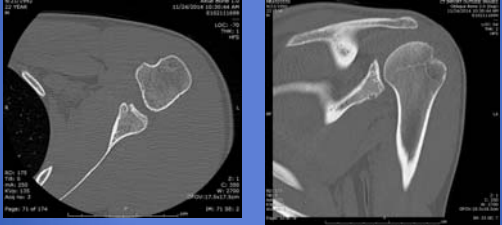CASE 3

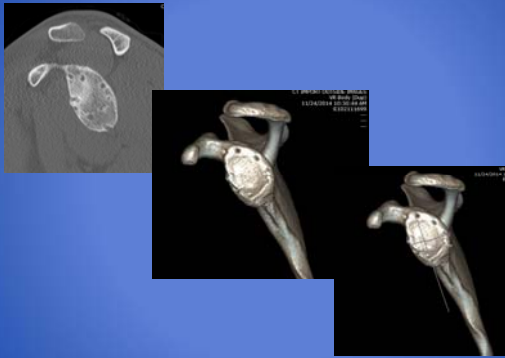
- 22 male
- Shoulder instability, comes out at night.
 - 1st scope procedure age 17
 - 2nd scope procedure age 19
 - Opposite shoulder 1 scope... "fine" but loose
 - Now 22 y.o.
 - Hyperlex—not EHD
 - Low abduction apprehension
 - "I want this to end"

2 Failed Scopes



2 failed scope 22 male

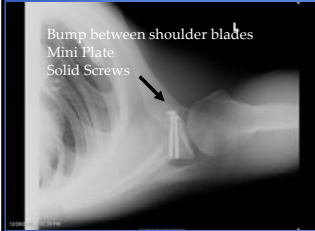




What would you do ?



Jury on LTJ



- Sling duration ?
- Post op CT ?
- Return to Sports?

- 2 weeks
- Nope
- 4 mo's'

*"You will never move normally again after that operation"
-2nd opinion at major institution*

Outcome

- Did great. Full motion. Stable.

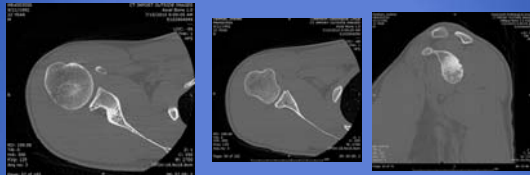
- 11.25 mo's later at 14:32 hrs.
- URGENT CALL, " shoulder is dislocated", please call ASAP.

Options

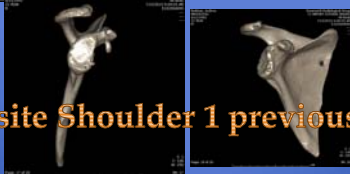
- Throw up
- Hyperventilate
- Have office tell them I haved moved
- Move
- OMFG. The NY guy was right....

- "Mrs Jones I am so sorry to hear he has hurt his other (opposite) shoulder"

Doc, I want the same operation



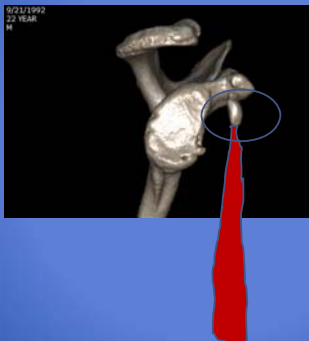
Opposite Shoulder 1 previous scope



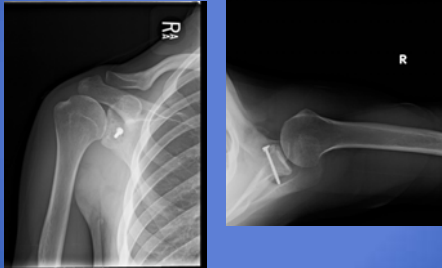
Options



• Fresco from Pompei

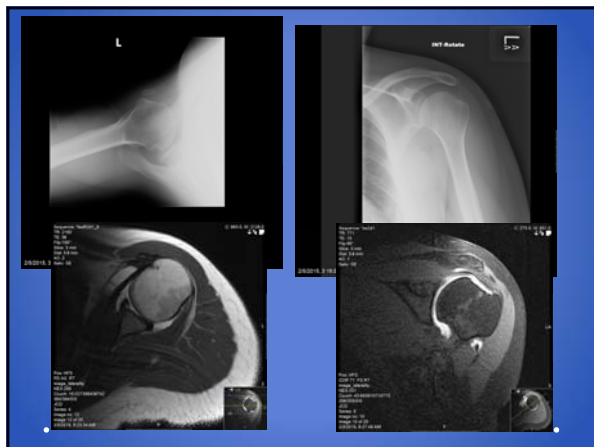


Is a Bristow Better than a LTJ..or vice versa ?

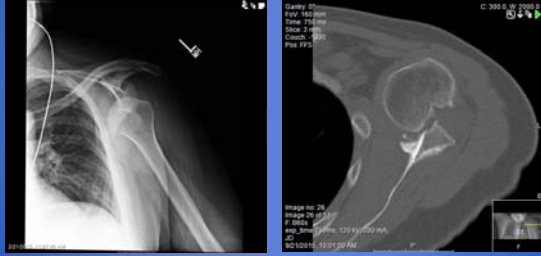

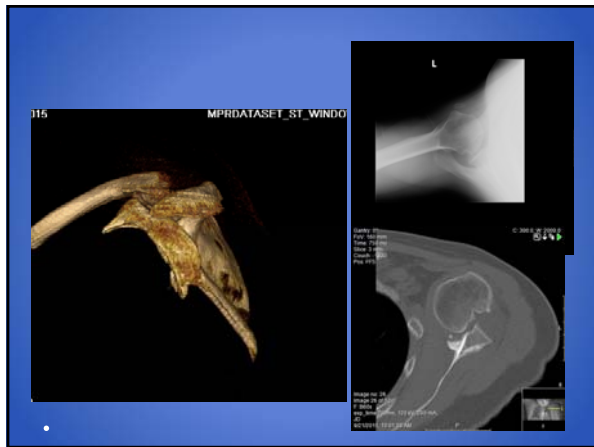
Yes, Dr. Mirzayan, I know that the screw is a little long. Just Shhh. Trust me, he just fine !!!


New Case



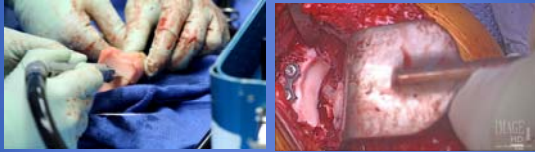
Got Deployed...its been
this way 6 weeks ?





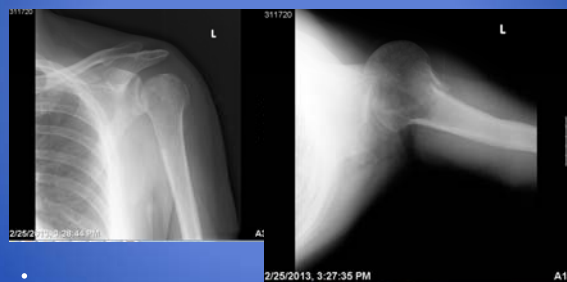

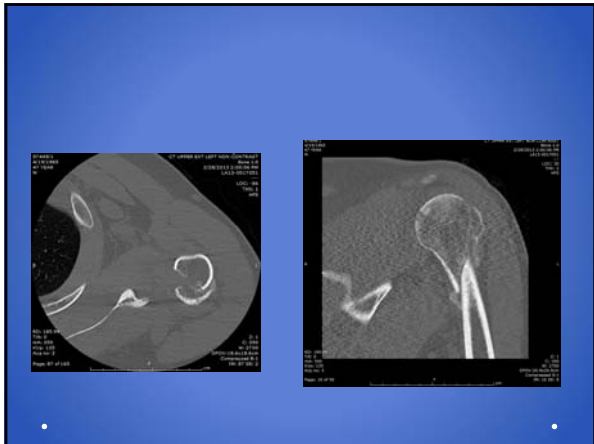Soft head...25 male....

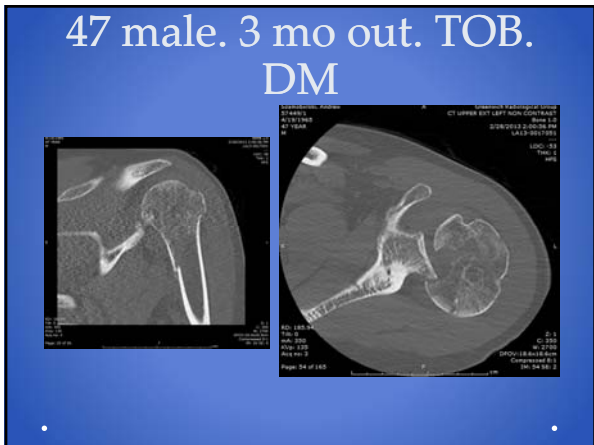


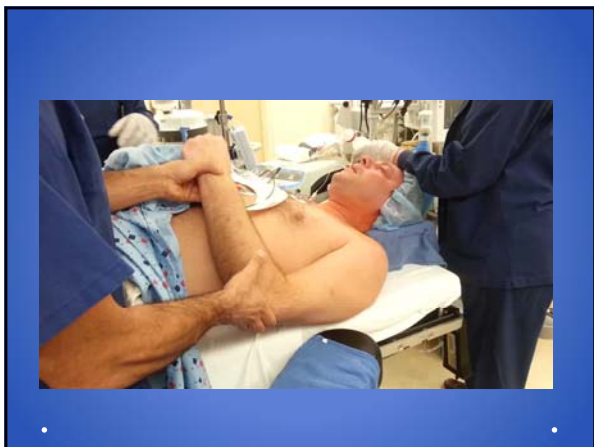
I have more...

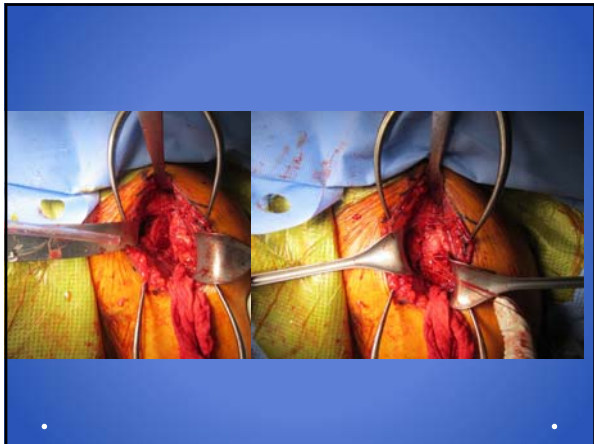
Nest Case : 47 Male

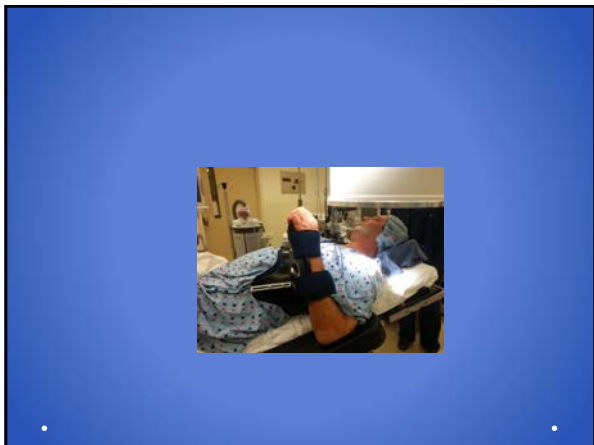






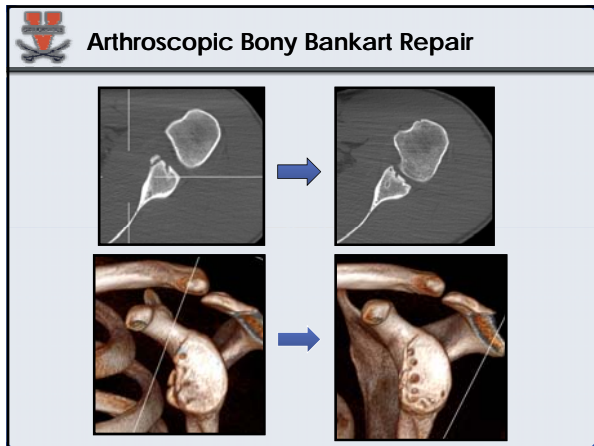


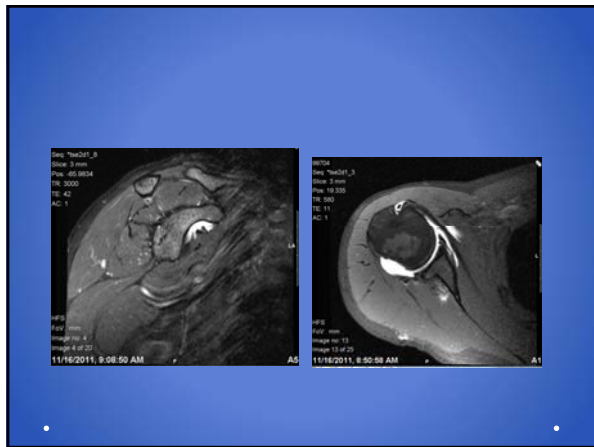





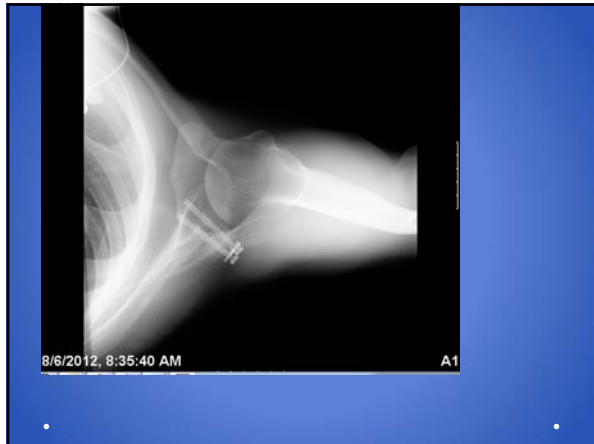Sophisticated Operations are for sophisticated people













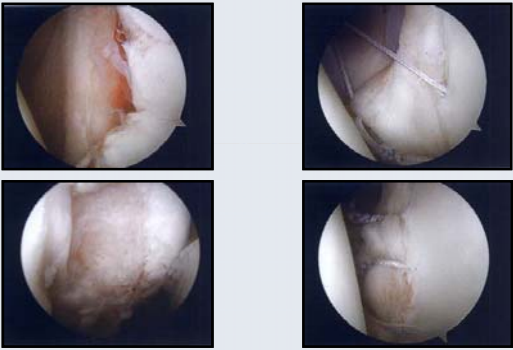


 **Case #1** 

- **19 yo D1 FB player, strong safety:**
 - Traumatic anterior instability event making a tackle in camp
 - Recurrence during the first game and unable to continue to play with a harness
- **Exam:**
 - + Apprehension
 - + Jobe,
 - Load/shift
- **MRI: anteroinferior labral tear with medialized position; small Hill-Sachs lesion**





 **Stabilization**



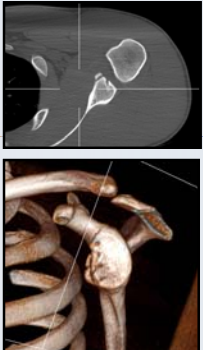
 **Case #1**


- Progressed normally
- Cleared for play ~6 months postop
- Full ROM, negative apprehension
- Played all spring and first part of the following season
- Feeling great, fully back when...





 **Case #1**

- Cleared for play ~6 months postop
- Full ROM, negative apprehension
- Played all spring and first part of the following season
- Feeling great, fully back when...
- Recurrent episode during practice
- Hit a running back who was moving past him through a running lane
- Imaging:





 **OK what now??**



 **Case #1**

- Anterior glenoid fx / bony Bankart
- Anchor holes?
- Recurrently unstable
- Now what???



 **Diagnostic Scope**

