ACL Technique: Independent Drilling

R. Alexander Creighton MD
Chief Sports Medicine UNC
Chicago Sports Medicine Symposium
8/15/15

Disclosures

- Arthrex: Institutional Support
- Depuy/Mitek: Institutional Support

Technical Failure: Non-Anatomic Tunnel Placement

- Cause of 70-80% failures (Getelman-JAAOS-1999)
  - Most common is improper placement of femoral tunnel
  - Tibial Tunnel placement is less critical

Tibial Tunnel Problems

Anterior
- Excessive strain in flexion
- Roof impingement

Posterior
- Excessive strain in extension
- PCL impingement

Medial/Lateral
- Impingement on condyle
- Plateau compromise

Tibial Tunnel Problems

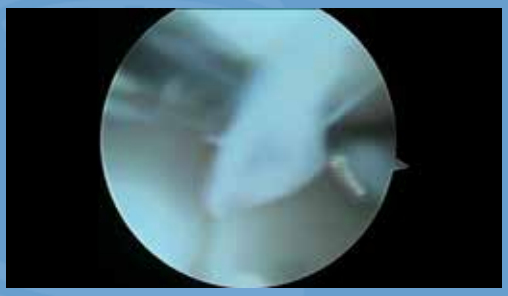

Femoral Tunnel Problems

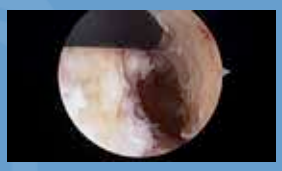

- Femoral
  - Anterior
    - Most common error
    - Laxity in extension
    - Constrained in flexion
  - Posterior
    - Laxity in flexion
    - Constrained in extension
    - Usually "never too posterior" = Blow Out
  - Central
    - AP stability
    - Rotational component not addressed
      - Pivot Shift still be present

Femoral Tunnel Problems

Anteromedial portal technique for creating the ACL femoral tunnel

- Harner et al Arthroscopy 2008
  - More flexibility
  - More anatomic
  - Preservation of remaining ACL fibers
  - Not limited to by choice of graft

Potential risks of femoral tunnel drilling through the far anteromedial portal: a cadaver study

- Nakamura et al Arthroscopy 2009
  - 10 cadaver knees, drilled AMB & PLB, 70-90-110
  - Low flexion angles risk of damaging common peroneal nerve and posterior articular cartilage
  - Risks decreased at higher flexion angle
    - Still 20% risk of posterior articular cartilage damage.

Transtibial vs anteromedial portal reaming in ACL reconstruciton: an anatomic and biomechanical evaluation of surgical technique

- Altchek et al. Arthroscopy 2011
  - 10 cadaver knees (5 matched pairs)
  - Transtibial or AM portal technique
  - AM technique restored
    - Anterior drawer, Lachman, and pivot-shift
  - Transtibial altered placement of ACL origin
    - 1.94 mm anterior & 3.26 mm superior
    - Tibial tunnel aperture 38% larger in AP dimension
  - AM portal technique allows for accurate positioning of femoral socket in center of native ACL footprint resulting in time-zero control of tibial translation vs TT technique

Anatomic femoral tunnel drilling in ACL reconstruction: use of an accessory medial portal vs traditional transtibial drilling

- Tompkins et al Am J Sports Med 2012
  - 10 matched cadaver knees
  - CT scan pre and post technique
  - AM technique
    - 97% +/- 5%
    - 3.6 +/- 1.2 mm from center of native footprint
  - TT technique
    - 61% +/-24%
    - 6.0 +/- 1.9 mm from center of native footprint
  - Conclusion AM technique will facilitate more accurate placement of the femoral tunnel in native ACL femoral footprint.

Increased risk of revision after AM compared with TT drilling of the femoral tunnel during primary ACL reconstruction: results from the Danish Knee Ligament Reconstruction Register

- Rahr-Wagner et al. Arthroscopy 2013
  - 9,239 primary ACL 1/2007 & 12/2010
    - 1,945 AM (13)in 2007, 40% in 2010
    - 6,430 TT
  - Revision ACL as primary endpoint
    - 5.16% AM vs 3.20% TT
  - 2nd endpoints pivot-shift and instrumented
  - Conclusion of increased risk of revision ACL with AM technique
    - New technique
    - Greater force is carried by the anatomic ACL

AM vs TT drilling in ACL reconstructions: a systemic review

- Chalmers et al. Arthroscopy 2013
  - 9 studies (5 clinical Level II or III and 4 cadaveric)
  - Rotational stability
    - 3 cadaver and 2 clinical improved for AM
    - 2 cadaver and 1 clinical study similar
  - Superior clinical outcomes
    - 2 studies showed superior clinical outcomes
    - 3 studies no difference
  - Conclusion AM portal technique may be more likely to produce improved clinical and biomechanical outcomes but the TT technique is capable of producing similar outcomes

TT vs independent drilling techniques for ACL reconstruction: a systemic review, meta-analysis, and meta-regression

- Riboh et al. Am J Sports Med 2013
  - Cadaveric, in vivo, and clinical studies
  - 49 studies in qualitative review
    - Improved accuracy 2.69 mm closer with ID
    - Lachman improved 2.2 mm and simulated pivot-shift
  - 15 studies meta-analysis
    - Improved Lysholm ID (-0.62 points) very small
    - No difference in IKDC or Tegner
  - 22 studies in meta-regression
    - No significant differences in failure rates or IKDC objective scores
  - Conclusion biomechanical data suggesting improved knee stability and more anatomic graft placement no significant clinical differences

TT ACL femoral tunnel preparation increases odds of repeat ipsilateral knee surgery

- Duffee A et al. J Bone Joint Surg Am 2013
  - Moon group 436 primary isolated
    - TT 229 pts vs AM 207 pts
  - Postoperative KOOs available for 387 (88.8%)
    - No difference
    - Repeat surgery 2.49 odds ration
  - TT technique resulted in higher odds of repeat ipsilateral knee surgery relative to those who underwent reconstruction AM technique

Femoral and tibial graft tunnel parameters after TT, AM, and outside-in single-bundle ACL reconstruction

- Osti M et al. Am J Sports Med 2015
  - Cohort study level III
  - 100 pts
    - Group 1 = TT (36), Goup 2 = AM (32), Goup 3 = OI (32)
  - CT scan used post-op
    - AP and sagittal tunnel axis improved with OI and AM
    - OI and AM more precise intercondylar depth and height
    - OI produced more oblique and anatomically correct femoral tunnel apertures and longer femoral tunnel lengths
  - Conclusion OI & AM techniques were superior in positioning ACL in center of native footprint compared to TT, All 3 techniques resulted in acceptable graft fixation length

My Technique

Garrett et al Arthrosc Tech 2015

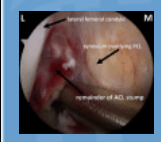

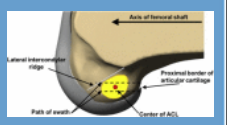

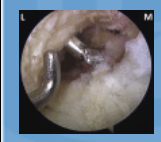

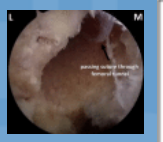

Soft Tissue Graft

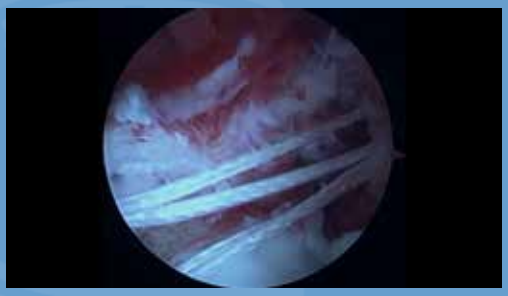

Conclusion

- Independent drilling can reproduce anatomic femoral insertion
- Clinical outcomes similar
- Learning curve to changing techniques

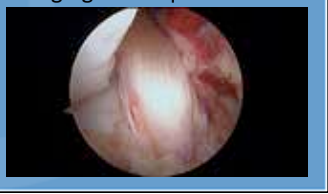

Thank You